



# HPV

AUSTRALIA AND NEW ZEALAND  
HPV PROJECT

The New Zealand HPV Project

## **Guidelines for the Management of Genital HPV in New Zealand**

6th Edition - 2010

Produced by the Professional Advisory Board (PAB)  
of the New Zealand HPV Project

# Viral Sexually Transmitted Infection Education Foundation Resources

## Helpline

### HPV:

Tollfree 0508 11 12 13

### HERPES:

Tollfree 0508 11 12 13

## Website

[www.hpv.org.nz](http://www.hpv.org.nz)

[www.herpes.org.nz](http://www.herpes.org.nz)

## Resources

### Patient Information Pamphlets

1. Some Questions and Answers about HPV and Genital Warts
2. A Patient Guide: HPV (wart virus) in perspective
3. Cervical Smears and Human Papilloma Virus Infection (HPV)
4. What every woman should know about Genital HPV (Human Papilloma Virus) Infection and the Cervical Cancer Vaccines

### Patient Information Pamphlets

1. The Facts: A guide for people with Herpes Simplex  
Includes -  
Genital Herpes - The Facts  
Herpes and Relationships  
Herpes and Pregnancy  
Facial Herpes
2. Herpes: Myth vs Fact

**These resources are available through the  
Viral Sexually Transmitted Infection Education Foundation**

**Phone: 09 433 6526**

**Fax: 09 360 2835**

**Email: [info@hpv.org.nz](mailto:info@hpv.org.nz)**

**or: [info@herpes.org.nz](mailto:info@herpes.org.nz)**

# **Guidelines for the Management of Genital Human Papillomavirus (HPV) in New Zealand**

**6th Edition - 2010**

Produced by the Professional Advisory Board (PAB)  
of the New Zealand HPV Project

1st Edition	1999
2nd Edition	2001
3rd Edition	2002
4th Edition	2004
5th Edition	2007

For a list of the Professional Advisory Board (PAB) members, refer to page 35.

© 2010 Viral Sexually Transmitted Infection Education Foundation

## ABOUT THIS DOCUMENT

This document is a consensus opinion of the Professional Advisory Board (PAB) of the New Zealand HPV Project. The PAB has representation from patients and medical and nursing bodies involved in the management of people with genital HPV and/or genital warts. A process was undertaken to evaluate contemporary international literature and develop best practice regarding the diagnosis, treatment and evaluation of patients with HPV infection/genital warts and their sex partners, in Australasia. The recommendations are based on strong evidence in the literature or reasonable suppositions and opinions of experts. The PAB works on a voluntary basis.

Commonwealth Serum Laboratories [CSL] provided an educational grant towards the publication of these guidelines, they did not participate in their development.

The guidelines' recommendations have been rated under the following evidence-based categories:

**GRADE A: Very strong evidence**

One or more properly randomised controlled clinical trials.

**GRADE B: Fairly strong evidence**

One or more well designed observational studies (i.e. non-randomised clinical trial cohort, case control or time series study; or non-controlled experimental trials).

**GRADE C: Weak evidence or firmly held opinion**

Opinions of respected authorities that were based on clinical experience, descriptive studies, and/or reports of expert committees.

## TABLE OF CONTENTS

3	Introduction
4	Epidemiology of Genital HPV Infection
6	Transmission of Genital HPV Infection
7	HPV and Cancer
8	HPV Vaccines
10	Clinical Presentation and Diagnosis
10	Molecular (DNA) Diagnosis of Genital HPV Infection
12	NCSP Flow Chart Guides
14	Treatment of Genital HPV Infection and Genital Warts
20	Table 1: Treatment by site
20	Table 2: Summary of treatment options
22	Table 3: Factors that may influence the selection of treatment for warts
23	Special Situations
25	Key Issues in Counselling
26	Key Information for Patients
27	Guidelines on the Management of HPV in Childhood
30	References
34	Clinical Presentations of Genital HPV
35	Professional Advisory Board

# HUMAN PAPILOMAVIRUS (HPV) AND ANOGENITAL CANCER

## Introduction

During the late 1970s, emerging evidence indicated the wart virus may be central in the pathogenesis of cervical and other lower genital tract cancers. Since that time, developments in the field of molecular medicine, together with many large epidemiological studies, have provided convincing evidence of the causal role of high risk (HR) HPV in cervical and many other lower genital tract, anal and oro-pharyngeal cancers. More recently, HPV vaccines have been developed and subjected to extensive field trials. These have demonstrated their safety and efficacy in preventing infection and disease caused by HPV types contained within the vaccine.

**R W Jones**

Chairman

# EPIDEMIOLOGY OF GENITAL HPV INFECTION

## KEY POINTS

- Ubiquitous infection with a prevalence of 20% in 20 year olds.
- The majority of infections are transient with 80-90% clearance within 2 years.

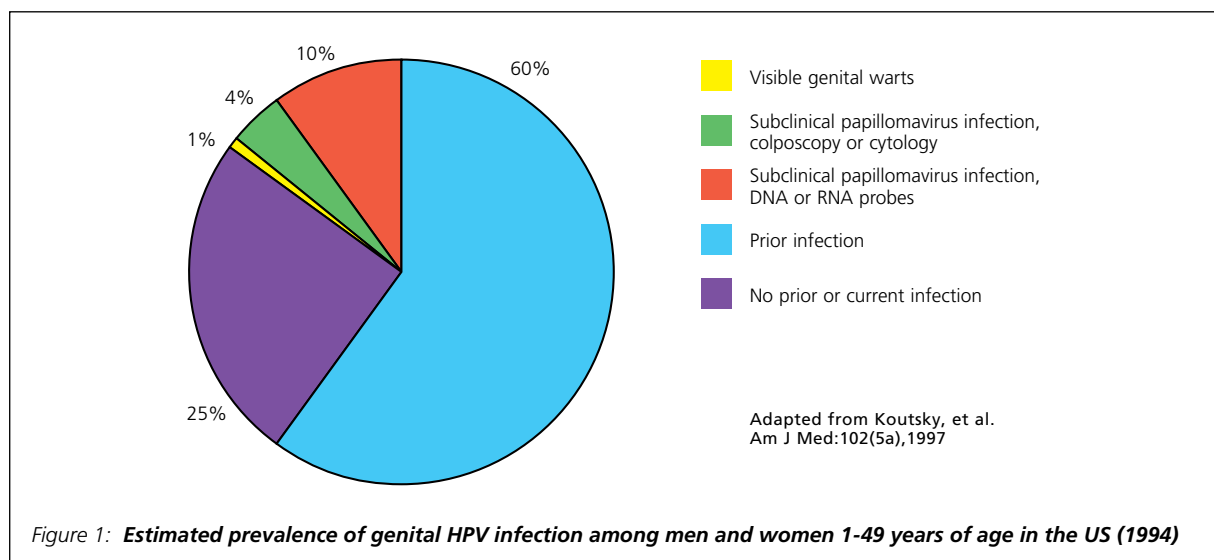
## Incidence and prevalence

HPV infection is ubiquitous, with approximately 75-80% of women being exposed to at least one HPV infection in their lifetime.<sup>1</sup> A recent review reported that at any given point in time 10.5% of women worldwide are positive for HPV DNA in the cervix.<sup>2</sup> A recent meta analysis estimated HPV prevalence among women with normal cervical cytology using data from 78 published studies.<sup>1</sup> The highest prevalence is in young women (20-25% around age 20) falling to 10% at age 30 and falling slightly thereafter.<sup>1</sup> A recent Australian study showed a high risk (HR) HPV prevalence of 23.6%, with highest rates in young women (age 15-19: 44%, age 20-24: 42%, age 25-29: 34%) and falling below 10% after age 40.<sup>3</sup> A small increased prevalence in women over 65 years may reflect reactivation of previously undetectable infection acquired earlier in life, new infections, or a cohort effect.<sup>4</sup> HPV prevalence in men is lower than women, as keratinised penile epithelium is more resistant to HR HPV.<sup>5</sup> Rates of HPV infection in young women are high following sexual debut. 28% after 1 year with 1 sexual partner increased to 49% after 36 months, and remain high with acquisition of each new partner.<sup>6,7</sup> Studies have reported cumulative incidences of 40% or more after 3 years of follow-up.<sup>4</sup> Evidence suggests the incidence of HPV infection is similarly high in men.<sup>5</sup>

HPV types 6 and 11 have been reported in 70% to 100% of visible genital warts. However, co-infection with other HPV types is also common.<sup>8-12</sup>

Visible genital warts have a reported prevalence of 1% in the United States.<sup>10,13</sup> In an Australian study on young women aged 18 to 23 years, the lifetime self-reported incidence of genital warts was 3.1%.<sup>14</sup> In the Dunedin Multidisciplinary Health & Development Study, Dickson et al determined the self-reported cumulative incidence of genital warts. At age 21, men reported an incidence of 4.7% and women 6.9%,<sup>15</sup> and at age 32, men reported an incidence of 10.2% and women 12.2%<sup>16</sup> (personal communication).

Most HPV infection is associated with initiation of sexual activity and is transient, although in some cases HPV infection remains latent and may reactivate years later.<sup>17</sup> There is a rapid clearance of HPV in the first 6 to 12 months, with 80 to 90% clearance by 2 years. Following this time there is a very small fraction of persistent infection that may progress to CIN II plus.<sup>18</sup>



## Factors associated with HPV acquisition

### KEY POINTS

- Genital HPV infection is common in people who have recently become sexually active.
- Most genital HPV infections are subclinical.
- On average, 75% of sexually active adults will have had some form of HPV infection.
- Increasing number of sexual contacts is associated with increased risk of genital warts.
- For most people, infection with each HPV type is transient and clears spontaneously within the first 6 to 12 months, but in some cases HPV infection persists or remains latent and may reactivate years or decades later.

### Sexual activity

HPV infection is, in most cases, a sexually transmitted disease and in both men and women risk acquisition is influenced by sexual behaviour.

A population-based case-control study on men showed having increasing numbers of partners in the previous 5 years was strongly associated with incident and recurrent condyloma acuminata.<sup>19</sup> There was some increased risk with a history of any sexually transmitted infection. A similar study on women also showed a strong association with multiple partners.<sup>12</sup> Women with 5 or more partners in the previous 5 years had a relative risk of 7.1 for incident warts and 12.8 for recurrent warts, compared to those who had one partner over this time period.<sup>7</sup> Winer et al showed that in female university students a report of a new partner was predictive of incident infection as measured by DNA positivity.<sup>7</sup> In the large WAVE III study involving women aged 18 to 25, having more than 3 lifetime partners was independently associated with HPV infection.<sup>20</sup> Interestingly, a recent study of global patterns of sexual behaviour reported the absence of decreasing age at sexual debut.<sup>21</sup> However, Australian surveys report the trend of declining age at sexual debut and an increasing proportion of students reporting more than 3 partners in the last year.<sup>22</sup> In a 2007 New Zealand survey, the prevalence of sexual activity increased across age groups 13, 15 and 17 years old with 16.8%, 33.3% and 48.7% reporting having had sexual intercourse, respectively.<sup>23</sup>

HPV transmission can be sustained in populations where individuals have few partners but relationships form serially or overlap briefly in time. The Jefferson High School study reported that during an 18 month period more than 50% of the students were linked through romantic and sexual relationships.<sup>24</sup>

### Oral contraception

There is conflicting evidence that oral contraceptive use increases the risk of genital warts,<sup>12,25</sup> however a study of 603 female university students demonstrated that use was predictive of cervical HPV DNA positivity.<sup>7</sup> It is also possible that the use of oral contraception is a surrogate marker for other sexual behaviours.

### Smoking

An association with cigarette smoking and cervical or penile HPV infection as demonstrated by HPV DNA has been shown.<sup>5,7,26-29</sup> The role of smoking in genital wart acquisition is conflicting.<sup>12,25,30-32</sup>

### Pregnancy

There has been variable reporting on HPV rates in pregnant versus non-pregnant women.<sup>13</sup> This may be due to higher levels of virus being found in pregnancy, possibly due to immune status.

### Role of immunity

Increased rates of HPV infection have been found in those with HIV. A case-control study compared renal transplant patients who were immunosuppressed with controls and found an increase in genital HPV.<sup>33</sup>

### Condom use

See section on transmission, page 6.

# TRANSMISSION OF GENITAL HPV INFECTION

## KEY POINTS

- HPV is highly infectious.
- If one member of a stable partnership has genital HPV infection, the other is likely to be either infected or immune to that infection.
- Condoms do provide limited protection against genital warts acquisition and CIN II and CIN III.

Direct skin-to-skin contact spreads HPV infection most efficiently. The virus is not transmitted via blood or body fluid, e.g. semen. Genital forms of the virus target the mucous membranes and adjacent genital skin. One early study demonstrated that 60% of sexual partners of those with genital warts subsequently developed them as well.<sup>34</sup> Using computer modelling, Barnabas et al estimated the per partner male to female transmission to be 60%.<sup>35</sup> Transmission occurs frequently because subclinical infections are common and asymptomatic, and warty lesions often go unnoticed, particularly in areas that are not easily inspected for the presence of warts.

Sexual contact is the most common form of transmission among adults. Vertical transmission in utero is very rare<sup>36</sup> (see HPV in Pregnancy section page 23). Autoinoculation may occur rarely.<sup>37</sup> It is possible, but very uncommon, to transmit genital HPV infection to the mouth through oral sex. The mouth appears to be a less hospitable environment for genital strains of HPV than the genital area.<sup>38-41</sup> While HPV DNA has been found on fomites or inanimate objects, there is no evidence to support transmission occurs.<sup>42,43</sup>

For management of HPV infection in children, see page 27.

The latency period of genital HPV infection is extremely variable. Often, warts will appear after 3 to 6 months, but latency periods of many months or even decades have been reported.<sup>44</sup> Evidence for such extended latency periods is seen in immunocompromised and normal patients who, despite having been sexually inactive for many years, can suddenly develop warts or cervical abnormalities. It is important to emphasise that developing genital warts during a long-term relationship does not necessarily imply infidelity.

It is generally believed, although not proven, that clinically visible warts offer the greatest possibility for transmission, and that treating warts decreases that possibility. As it is difficult to detect HPV in its latent stage, it is impossible to know whether in some cases the immune system can completely clear the virus from the body, or whether the virus remains latent at undetectable levels, capable of re-emerging if the immune system weakens. Manhart et al reviewed effectiveness of condoms in prevention of HPV disease, analysing 27 studies, and concluded that there was no consistent evidence that condom use reduced the risk of becoming HPV DNA positive.<sup>45</sup> A recent study confirmed this finding in women. Condom use did, however, provide some protection against genital warts, although precise estimates were not available because of data inconsistency. There was some protection against cervical intraepithelial neoplasia (CIN) II and CIN III. The authors postulated that although condoms might not alter the rate of HPV infection (as measured by DNA analysis) the amount of virus may be decreased with consequent change in probability of disease expression. More recently, however, a study with 82 female university students did show a significant decrease in genital HPV infection as measured by HPV DNA when condoms were used all the time, as compared with use only 5% of the time.<sup>46</sup>

# HPV AND CANCER

## KEY POINTS

- HIGH RISK HPV IS A NECESSARY CAUSE OF CERVICAL CANCER.
- HPV is associated with a significant number of vulval, vaginal, anal, and penile cancers.

The infectious cycle of the human papilloma virus begins when infectious particles breach the epithelium of the lower anogenital tract and enter basal epithelial cells. Basal stem cells then divide and mature vertically through the epithelium without further division. The virus replicates into suprabasal/squamous cells and is released into the environment when the superficial cells desquamate. The E6 and E7 viral proteins are critical in the viral replication process and differences between these proteins in the high and low risk HPV types determine interactions with cell cycle proteins (pRb and p53), which in turn determine cellular proliferation or malignant transformation.<sup>47</sup>

From the 1980s, epidemiological studies have provided increasing evidence to suggest HPV is the aetiological agent in cervical cancer.<sup>48</sup> In 1995, the International Agency for Research in Cancer (IARC) stated that HPV 16 and 18 are carcinogenic, with limited evidence of the carcinogenicity of HPV 31 and 35.<sup>49</sup> Since then, the IARC has demonstrated HPV DNA in 99.7% of approximately 1,000 cervical cancers from 22 countries.<sup>50,51</sup> In addition, many vulval, vaginal, anal and penile cancers are HPV related.<sup>52</sup> HPV 16 and 18 account for about 70% of all cervical cancers worldwide, with some regional variations, e.g. HPV 16 and 18 account for 77% of cases in Oceania.<sup>53</sup>

HPV can infect the entire lower genital tract, but there is a predilection for CIN and cancer to occur in the immature epithelium of the 'transformation zones' in the cervix and anus.

While the morphological spectrum CIN I to II to III is useful from a cyto/histopathology perspective, it is less useful in understanding the role of HPV in carcinogenesis, since microscopic abnormalities are only seen in a minority of women with HPV DNA detected by DNA assay. From a practical perspective, e.g. natural history, CIN I and HPV should be viewed as similar lesions. HPV type, viral load and persistence are more important than the presence or absence of microscopic evidence of infection such as koilocytosis.<sup>54,55</sup> Low viral load infections (e.g. detectable only by PCR) are less likely to be associated with microscopic changes and risk of subsequent pre-cancer compared with high viral load infections.<sup>56</sup> The median time for clearance of prevalent infections varies from 6 months to 1 to 2 years, with 90% clearance of specific HPV types within 2 years.<sup>54</sup> Persistent infection is a marker for the development of CIN II and III. HPV 16 persists longer than other types, with an absolute risk of CIN III approaching 40% after 5 years' persistence.<sup>57</sup>

The previous view that the 'high risk' woman (for developing CIN II or III and cancer) was the woman with a history of an early coitarche, multiple sexual partners etc, must now be replaced by the concept that persistent HR HPV infection is the most important risk factor.

CIN III must be regarded as the surrogate end point for cancer. However, CIN II lesions may represent severe cytological changes associated with HPV infection that are destined to regress, while others are destined to persist with risk of progression. The median age of women with CIN III is 27 to 30 years. However, intensive prospective follow-up of women in their early 20s has demonstrated the rapid development of CIN II and III, often within a few months of incident infection.<sup>58</sup> Women with cervical screen detected invasive cancer are 10 years or more older than the median age of women presenting with CIN III.<sup>54</sup> Recent New Zealand data have demonstrated that, in women with CIN III managed only with small diagnostic biopsy and persistent abnormal smears, the cumulative incidence of invasive cancer of the cervix was 50%.<sup>59</sup>

HPV also causes a portion of vulval (20 to 50%), vaginal (60 to 65%) and anal (85%) cancers, with HPV 16 accounting for the vast majority. The immediate precursor lesions are vulval, vaginal and anal intraepithelial neoplasia (VIN, VAIN, AIN). New Zealand studies have demonstrated VIN to have a significant invasive potential in women age 30 years and over with a mean transit time to invasion of 4 years.<sup>60</sup> Investigation of the role of co-factors for persistence and progression is difficult because of the ubiquitous and transient nature of HPV infection. Cigarette smoking,<sup>61,62</sup> long-term use of hormonal contraceptives<sup>63</sup> and high parity<sup>64</sup> and coinfection with HIV have been consistently demonstrated as co-factors for cervical cancer.<sup>47</sup>

# HPV VACCINES

## KEY POINTS

- Both vaccines are safe and highly effective in preventing the HPV types associated with cervical cancer and precursor lesions caused by HPV types 16 and 18.
- Warts caused by types 6 and 11 can be prevented by the quadrivalent vaccine.
- Ideally, individuals should be vaccinated prior to sexual exposure.
- To date, protection has been demonstrated to be stable for up to 8 years and modelling suggests it will be sustained long term
- HPV immunisation (with the quadrivalent Vaccine Gardasil) has been added to the National Immunisation schedule for girls in school year 8, with a phased catch-up programme for girls born from 1 January 1990.

The principal reason for the development of HPV vaccines is the prevention of HPV-related lower genital tract malignancy, particularly of the cervix and the prevention of genital warts. Virus-like particles (VLPs) made of HPV L1 major capsid proteins are used in HPV prophylactic vaccines. VLPs are neither infectious nor oncogenic since they lack viral DNA. Therapeutic vaccines are under development and are unlikely to be available in the foreseeable future.

### What HPV vaccines are available?

Merck & Co (Gardasil – marketed by Commonwealth Serum Laboratories [CSL] in New Zealand) and Glaxo Smith Kline (GSK – Cervarix) have both developed vaccines that have been licensed in New Zealand. Gardasil contains VLPs for HPV types 6, 11, 16 and 18 and Cervarix VLPs for HPV types 16 and 18. Gardasil is licensed in females aged 9 to 26 years and males aged 9 to 15 years. The New Zealand Government introduced funding for the quadrivalent vaccine (Gardasil) in 2008. This has been added to the New Zealand immunisation schedule for girls in school year 8 (or aged 12 if not delivered in a school-based programme) on an ongoing basis, with a phased catch-up programme available to girls born on or after 1 January 1990. In Canterbury, this programme is being administered through General Practice.

### How effective are the vaccines?

In 2002, Koutsky et al reported the first randomised double-blind placebo-controlled trial of a monovalent HPV 16 VLP vaccine in 2400 young women.<sup>65</sup> This vaccine was 100% effective in preventing both HPV 16 infection and HPV 16-associated cervical intraepithelial neoplasia for at least 3.5 years after vaccination. 99% of vaccinated women seroconverted, i.e. becoming anti-HPV 16 antibody positive.

In 2007 the Future II study published data indicating the efficacy of quadrivalent HPV vaccine in the prevention of high grade cervical lesions.<sup>66</sup> In women naïve to HPV 16 or 18, the efficacy against CIN II or III, adenocarcinoma in situ or cervical cancer related to HPV types 16 or 18 was 98%. In the population at large, this figure reduced to 44% with almost all affected women in the vaccine group (98%) having evidence of infection 'that was present before the first injection'. This strengthens the argument for vaccinating women prior to onset of sexual activity.

In those women naïve to HPV 16 or 18 who followed protocol, the quadrivalent vaccine was 100% effective in preventing VIN 2-3, VAiN 2-3 associated with these types.<sup>67</sup> In those women who may have been exposed to those types, the efficacy was 71%.<sup>67</sup> This quadrivalent vaccine is highly effective (100% at 3 years) in the prevention of genital warts.<sup>68</sup>

Among women who are positive to one or more vaccine types 6, 11, 16 or 18, quadrivalent HPV VLP vaccine provides high level protection against disease related to the remaining HPV types.<sup>69</sup>

Phase 3 data from the GSK vaccine (Cervarix – currently not funded in New Zealand) have demonstrated 100% efficacy against persistent infection and 93% against cytological abnormalities associated with HPV 16 and 18, with follow-up extending to 7.3 years.<sup>70-72</sup>

### **How safe are these vaccines?**

Both vaccines are safe and well tolerated in all age groups. The majority of adverse events were reported as mild or moderate, with injection site reactions the most common.<sup>73</sup>

### **Who should be vaccinated and when?**

The quadrivalent vaccine, Gardasil, is licensed in New Zealand for females aged 9 to 26 years and males aged 9 to 15 years. However, public funding through the National Immunisation Schedule is available only for girls aged school year 8 (or age 12 if not delivered in a school-based programme), with a phased catch-up programme available for girls born on or after 1 January 1990. While not publicly funded for males, the vaccine is safe, well tolerated, produces high seroconversion rates in 9 to 15 year old males, and in males aged 16 to 26 years has been shown to be effective in decreasing the incidence and persistence of infection with HPV 6, 11, 16, 18.<sup>74,75</sup>

These vaccines have no therapeutic effect, i.e. patients with established genital warts or CIN caused by the relevant HPV vaccine type will not benefit from the vaccine.

### **How long will they last?**

The vaccines are highly immunogenic, and although the duration of immunity is unknown, stable protection has been so far observed for 8.1 years for monovalent HPV 16 vaccine<sup>76</sup> and 7.3 years for bivalent HPV 16, 18 vaccine.<sup>76</sup> Mathematical modelling suggests that protection from vaccination may be sustained long-term.<sup>77,78</sup> Immune memory is a hallmark of vaccines that induce longterm protection. The quadrivalent HPV vaccine formulated on proprietary aluminium adjuvant is highly immunogenic and exhibits excellent immune memory as evidenced by the rapid and robust increase in vaccine type specific antibodies in response to a further dose of the vaccine.<sup>79</sup>

### **Will cervical screening still be needed?**

Yes. Irrespective of whether a woman has been vaccinated, routine cervical screening will need to continue for the foreseeable future. This is because of possible prior infection with HPV types causing CIN, or new infection with other HPV types not covered by vaccination.

### **The vaccine and pregnancy**

These vaccines are not recommended for use in pregnancy. Completion of the vaccine course should be deferred if a woman is found to be pregnant. There is no evidence from the clinical trials that administration of the Gardasil vaccine adversely affects fertility, pregnancy, or infant outcome.<sup>66</sup>

### **Will less common genotypes replace types 16 and 18?**

In theory, widespread vaccination may allow less common genotypes to replace the vaccine types but expert opinion believes this to be unlikely.<sup>80</sup>

# CLINICAL PRESENTATION AND DIAGNOSIS

Subclinical HPV infection is asymptomatic and usually diagnosed by finding cytological abnormalities consistent with HPV infection on a cervical smear or by HPV viral detection methods.<sup>80</sup> Genital warts are visible lesions that occur in the anogenital area and there is good correlation between physical findings and histological studies. They appear as discrete lesions or may coalesce into confluent plaques. They may be skin coloured, red, white or brown. Smooth papular warts tend to occur on fully keratinised skin (labia and shaft of penis), condylomata acuminata occur most commonly on moist mucosal surfaces, and flat-topped papular external genital warts can occur on either surface. Genital warts are frequently multifocal (one or more lesions at one anatomic site, e.g. vulva), or multicentric (lesions on disparate anatomic sites, e.g. perineum and cervix).<sup>81-83</sup> It is important to examine the entire lower genital tract for the presence of multicentric visible warts before treatment.

Evaluation for intra-anal warts by anoscopy is recommended for men and women with recurrent perianal warts and/or a history of receptive anal intercourse. Urethromeatoscopy using an auroscope may help assess meatal warts in males.

## Differential diagnosis

The differential diagnosis of genital warts in women includes lesions which cause papules, plaques and flat erythematous lesions. Genital papules include normal anatomic structures such as vestibular papillae and sebaceous glands (Fordyce spots). Acquired papules and plaques include seborrhoeic keratoses, molluscum contagiosum, psoriasis, lichen nitidus, lichen planus, skin tags, melanocytic nevi, angiomas and condylomata lata.

Usual type vulvar intraepithelial neoplasia (VIN) usually presents as white, red or pigmented papules or plaques which may be pruritic, but can be asymptomatic. The lesions may have a warty surface and can be unifocal or multifocal. A lesion may be small and discrete or may be an extensive plaque covering most of the vulva or perianal skin. It may be clinically indistinguishable from the papular form of external genital warts, but appears more disorganised.<sup>84,85</sup> Histological examination of these lesions shows high-grade intraepithelial neoplasia: VIN is usually associated with HPV type 16 infection.

In men, papular lesions other than warts include sebaceous glands (Tyson's glands), pearly penile papules (angiofibroma), and Bowenoid papulosis (a type of in situ neoplasia which usually resolves spontaneously). Flat erythematous lesions include psoriasis, seborrhoeic dermatitis, lichen planus, Zoon's plasma cell balanitis, balanitis circinata associated with Reiter's syndrome, and in situ neoplasia of penile intraepithelial neoplasia (PIN) skin.

A number of clinical variants of PIN are recognised; many are associated with HPV type 16<sup>86</sup> (see page 34 for pictures).

# MOLECULAR (DNA) DIAGNOSIS OF GENITAL HPV INFECTION

Virological diagnosis of HPV relies on detection of viral DNA. A variety of DNA detection methods are available.

Polymerase chain amplification (PCR) of a short region of specific viral DNA is probably the most sensitive method.<sup>87</sup>

HPV testing is now used as an adjunct to cervical cytology in some situations. A number of validated commercial tests are being used in New Zealand.

HrHPV testing has been repeatedly found to have a high negative predictive value (~99%) and to be more sensitive for detecting risk of high-grade abnormalities than conventional cytology, which is generally a more specific test. It is the strong negative predictive value of HrHPV testing that has most effective clinical use in conjunction with cervical cytology. HPV test alone does not detect cell abnormality.

For HrHPV testing, liquid-based cytology (LBC) is preferred and has practical advantages in that it offers a platform for combined cytology and HrHPV testing on one cervical smear sample. Reflex testing is based on the outcome of cytology and unless LBC was used or a co-collected sample is taken, the woman would need to be called back. As from 1st July 2010, the NCSP will use only LBC.

## **HPV testing in the National Cervical Screening Programme (NCSP)** (The full NCSP Guidelines can be accessed on [www.nsu.govt.nz/Health-Professionals/2747.asp](http://www.nsu.govt.nz/Health-Professionals/2747.asp))

The areas of management of asymptomatic women with abnormal cervical smears within the NCSP that may benefit from HrHPV testing include the following:

### **The triage of women 30 years and over with ASC-US or LSIL cytology (without an abnormal smear in the last 5 years)** (see Chart 1 on page 12)

- 'Reflex' testing of women with ASC-US/LSIL eliminates the need for shorter interval repeat cytology testing. A normal test can reassure a woman that she is very unlikely to have a significant lesion and can reduce the need for colposcopy.
- Women with ASC-US/LSIL smears who test positive for HrHPV should be referred to colposcopy.
- Women who are found to be HrHPV negative can be followed up with repeat cytology testing at 12 months.
- Following a negative cytology result at 12 months, a woman can return to normal 3-yearly screening.

### **The follow-up of women who have been treated for a high-grade lesion (HSIL/ASC-H) within the last 3 years** (see Chart 2 on page 13)

- Women who have been previously treated for CIN II/III are at a small increased risk of further disease and cervical cancer. Recurrence may be due to limitations of colposcopy, inadequate treatment/persistent disease or new infection.
- HrHPV testing allows better identification of women at risk of persistent or recurrent lesions, while enabling many women to return to normal screening intervals.
- Women treated for CIN II/III should in the first instance undergo follow-up colposcopy and cytology within 6 to 12 months after treatment.
- HrHPV testing and cytology should then be carried out 12 months after treatment and annually thereafter until a woman has tested negative by both tests on 2 consecutive occasions, 12 months apart. A woman can then return to a normal 3-yearly screening interval.
- It should be noted that HrHPV testing should not be carried out sooner than 12 months after treatment of high-grade lesions, as viral clearance may take more than 12 months to occur.

*As indicated in Flowchart HPV Testing Guidance 2 (pages 51 and 52 of Guidelines for Cervical Screening in New Zealand).*

### **Women with high-grade lesions (HSIL/ASC-H) more than 3 years previously, treated or untreated and currently managed by cytology alone (historical testing)** (see Chart 3 on page 13)

- This group of women currently managed by annual cytology for more than three years, with all tests assessed as negative, would benefit from double testing (cytology and HrHPV).
- HrHPV testing and cytology should be carried out and annually thereafter until a woman has tested negative by both tests on 2 consecutive occasions, 12 months apart. A woman can then return to a normal 3-yearly screening interval.
- Those women who test positive for HrHPV despite repeated negative cytology are likely to have a very low risk of CIN1/111 and can be retested with cytology and HrHPV annually.
- Refer to colposcopy for any clinical concern.

## Post colposcopy management of women with discordant results e.g. high-grade cytology and negative, satisfactory colposcopy

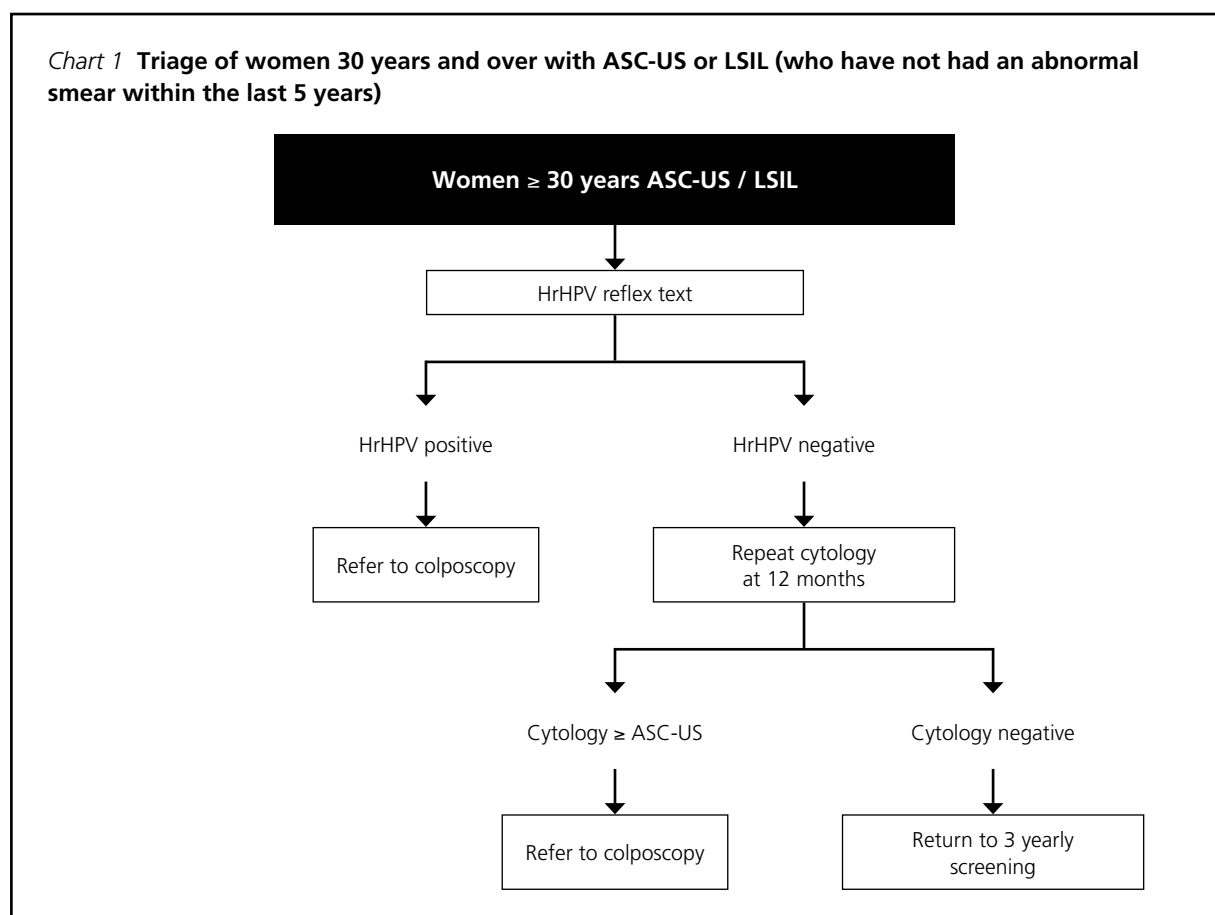
- A single colposcopic examination can miss significant lesions.
- Where findings on colposcopy/histology are negative or show low-grade changes only and the discordance persists following case review, HrHPV testing can be a useful adjunct to further management.
- The NCSP recommends a woman return to 3-yearly screening only after 2 negative sets of HrHPV plus cytology tests 12 months apart.
- Failure to detect CIN II/III lesions in a woman with high-grade cytology (following review of the smear) should lead to consideration of a diagnostic excisional procedure, or observation for 1 year with colposcopy, cytology and HPV testing.

Women with a history of genital warts do not need to begin screening at an earlier age or more frequently.

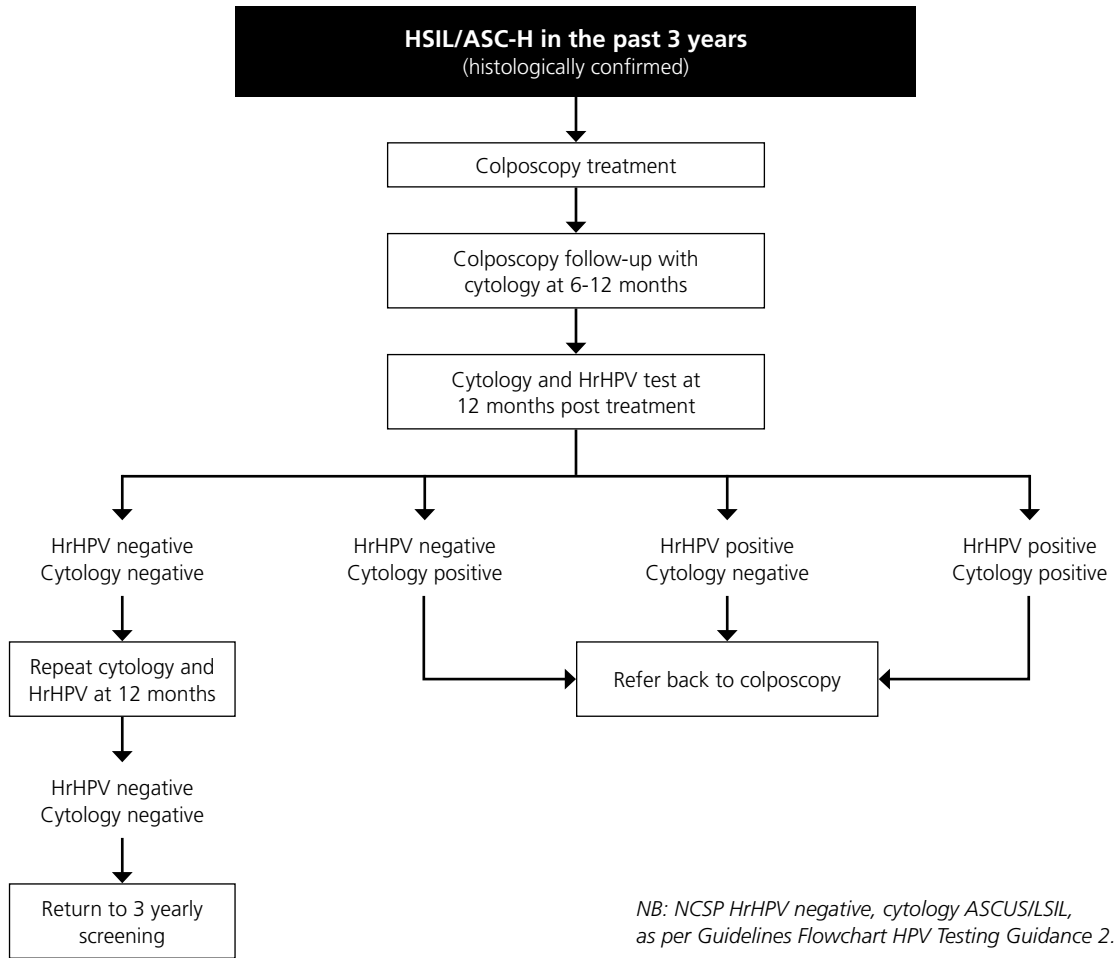
## Samples required for HrHPV DNA detection and typing

1. Specimens are collected using a broom-type collection device and either:
  - vigorously rinsed in the sample vial fluid if using ThinPrep (do not leave the broom head in ThinPrep vial), or
  - the head of the device must be detached and placed into the vial fluid if using SurePath.If a swab is taken then refer to your testing laboratory for advice on the appropriate collection and transport media.
2. Liquid-based cytology sample (ThinPrep or SurePath) sent directly to laboratory by smear taker. This sample needs to be taken and sent in accordance with your local lab protocol.
3. If lubrication is necessary, NCSP recommends use of warm water where possible or lubricant sparingly (KY Jelly only) because lubricant can mask cells.

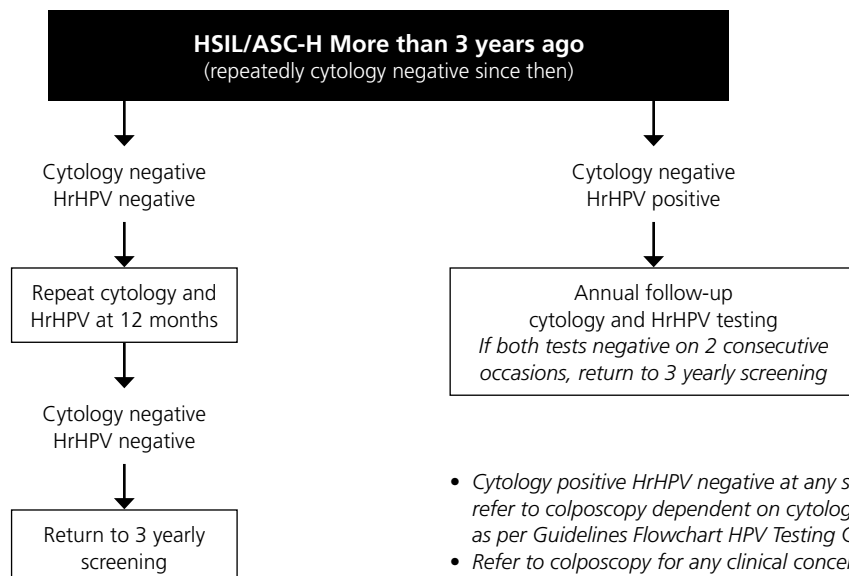
**NB: The following charts are taken from NCSP Guidelines, see [www.nsu.govt.nz/Health-Professionals/2747.asp](http://www.nsu.govt.nz/Health-Professionals/2747.asp)**



**Chart 2 HrHPV testing of women with a previous high grade lesion following colposcopy within the last 3 years**



**Chart 3 HrHPV testing of women with a high grade lesion more than 3 years previously, with subsequent repeated negative cytology tests (historical testing)**



# TREATMENT OF GENITAL HPV INFECTION AND GENITAL WARTS

## KEY POINT

- The primary goal of treatment is to eliminate warts that cause physical or psychological symptoms. Non treatment is an option for asymptomatic warts and the cure should not be worse than the disease.

There is no definitive evidence that any one treatment is superior to the others and no single treatment is suitable for all patients or all warts.<sup>88</sup>

The method of treatment should be determined by patient preference, available resources and the experience of the practitioner. Other factors include the size, number and site of the warts, the age of the patient and whether the patient is pregnant.

Commonly used treatments in primary care are self-administered podophyllotoxin or imiquimod, and practitioner administered cryotherapy.

If there is no significant response within 4 to 6 weeks, an alternative diagnosis, change of treatment modality, or onward referral should be considered.

Patients should be given information about all the treatment options in order for them to make an informed decision about their preferred choice.

Continuing lack of response to therapy should be referred to a relevant specialist.

## Subclinical infection

There is no specific treatment for subclinical HPV infection, which is usually temporary and resolves spontaneously.<sup>89</sup> Women who have cervical HPV infection should have follow-up cervical smears as advised by their health care providers in accordance with the National Cervical Screening Guidelines.

## Genital warts

There is a wide overlapping range of reported response rates and recurrence rates for individual treatments, and few comparative trials, making evidence-based choices of treatment difficult.<sup>90</sup> At present there is no ideal treatment for all patients or all warts and spontaneous resolution may occur. 20% may resolve spontaneously in 6 months.<sup>91</sup> A cohort study in men demonstrated that although there was no significant difference in the time to cure between those who received treatment compared to those who were not treated, there was a significant decrease in the number of warts and fewer new lesions appeared.<sup>90</sup>

The primary goal of treatment is to eliminate warts that cause physical or psychological symptoms. Physically, warts are often asymptomatic but can be painful, friable or pruritic. Emotionally, warts may be socially stigmatising or aesthetically upsetting.

Although treatment can result in a clinically free state, the underlying viral infection may or may not persist.

The elimination of external visible warts may not decrease infectivity since the warts may not represent the entire viral burden, as internal sites and clinically normal skin may act as reservoirs for HPV infection. Warts rarely progress to cancer.

Treatment should be discussed with the patient and tailored to their infection and needs, as well as to available resources.

Patients should be given information about all treatment options (including non treatment) in order for them to make an informed decision about their preferred choice.

Not all treatments are funded and the availability of some options may be restricted.

Presentation may also influence treatment choice, with warts on moist, partially keratinised surfaces and intertriginous areas responding better to topical treatments than do warts on dry, fully keratinised surfaces and open areas. Aggressive ablative therapy should be avoided over the clitoris, glans penis, urinary meatus, prepuce, and prepuccal cavity in uncircumcised men. Perianal warts, and often genital warts in women, as they cannot be adequately visualised, are not suitable for application of podophyllotoxin.

For a summary of treatment by anatomic site and treatment options, see tables 1 and 2, pages 20-21.

## Self-applied treatments (home therapy)

Self-applied treatments include the immune enhancer imiquimod (Aldara™) cream and the chemical ablative podophyllotoxin (Condyline™ solution and Warticon™ cream). These are first-line treatments in the United States. Patients must be able to follow application instructions to successfully use these therapies and careful explanation of their use is important. Higher than recommended doses of both of these applications may lead to an increase in adverse skin reactions.<sup>88</sup>

### Imiquimod

Imiquimod (Aldara) is fully subsidised for patients who have external anogenital warts and podophyllotoxin has been tried and failed (or is contraindicated), or where podophyllotoxin is unable to be applied accurately to the site. Clinicians will need to make Special Authority applications for this subsidy.

**Mechanism of action:** An immune enhancer that stimulates production of interferon and other cytokines. It appears to have an advantage of reduced recurrence rate.

**Suitable for:** Women, and some men with foreskin-associated warts. Particularly useful for 'carpet warts', e.g. female introitus and perianal area.

**Contraindications:** Not currently recommended in pregnancy. A register of imiquimod use in pregnancy has been established.\*

**Application:** Careful application of imiquimod cream is important.

Applied onto fingertip and rubbed onto clean, dry, wart area until cream vanishes, once daily, 3 times per week, prior to normal sleeping hours and after sexual activity (imiquimod weakens condoms and vaginal diaphragms). Wash off next morning or after 6-10 hours.

The manufacturer recommends that a sachet be used for single use to cover an area of up to 20cm<sup>2</sup>. However, it has been demonstrated that one sachet will cover up to 386cm<sup>2</sup> and, although not recommended by the manufacturer, one sachet is commonly used for multiple applications.<sup>92</sup> It is recommended that treatment should be continued until the warts have resolved, or up to a maximum of 16 weeks per course.

A preliminary study involving a small number of largely pre-treated women showed that a 4 week course of imiquimod was as effective as longer courses of 8, 12 and 16 weeks, with fewer adverse reactions and reduced cost.<sup>92</sup> The majority of women who cleared their warts did so by 8 weeks regardless of the duration of treatment, suggesting that imiquimod prompts a cell-mediated response with specific T-cell immune memory within the first 4 weeks.

**Side effects:** Localised erythema, swelling and/or rarely superficial ulceration of the treated area can be expected from 2 to 6 weeks as part of the immune response and will probably be related to the direct therapeutic action of the agent, i.e. switching on the immune response rather than to hypersensitivity. If indicated, the clinician may advise the patient to miss the next 2 applications, use salt water baths as well as drying with a hairdryer before recommencing treatment. These local skin reactions cause discontinuation of the treatment in less than 2% of patients.

\* 3M Monitoring System in Pregnancy:  
Pharmacovigilance Unit, 3M Health Care Ltd, Morley Street, Loughborough, Leicestershire, LE11 1EP, UK.

## Podophyllotoxin

Podophyllotoxin is dispensed in 2 forms, as a 0.5% solution (Condyline™) and as a 0.15% cream (Warticon™). These contain purified podophyllin in a more standardised form. Podophyllotoxin has been extensively studied in randomised and placebo-controlled trials.

**Mechanism of action:** The active moiety is an antimitotic and causes localised tissue necrosis. Localised epidermal pallor, caused by intracellular oedema, can usually be seen within 48 hours of application.

**Suitable for:** Small external warts which can be visualised. May be less effective for keratinised warts.<sup>88</sup>

**Contraindications:** A history of hypersensitivity (incidence approximately 1%). They are not used in pregnancy or lactation, or in children. Should not be used on warts which cannot be visualised, on internal warts, and they are not recommended for extensive wart areas (>10cm<sup>2</sup>).

**Application:** Patients must be able to visualise, identify and reach their warts, and if necessary should be shown what is wart and what is normal skin, using a mirror. Podophyllotoxin solution should be applied carefully to the warts using one of the applicators enclosed with the product, taking care that the solution does not come into contact with healthy skin and allowing drying after application to avoid inadvertent spreading of the solution. Applying Vaseline or zinc ointment on healthy skin around the wart(s) can be protective. The cream Warticon™ is applied directly by finger and may be more easily applied by women and in the treatment of perianal warts. The solution or cream should be applied twice daily for 2 to 3 consecutive days each week until the warts have resolved, or for a maximum of 5 consecutive weeks.

**Side effects:** Mild erythema with slight pain and/or superficial ulceration of the treated area can be expected. More severe skin ulceration, erosions, erythema, irritation, scarring, phimosis, pain, burning and soreness can occur. These effects are usually only mild to moderate in severity and resolve when the warts necrose.<sup>88</sup>

## Physician-applied treatments

### Cryotherapy

**Mechanism of action:** Destroys the wart tissue by freeze/thawing, resulting in sloughing and wart destruction.

**Suitable for:** External and internal warts. Dry and moist warts. Can be used in pregnancy.

**Contraindications:** Cryoglobulinaemia.

**Application:** Adequate training and expertise in this technique is required. Effective cryotherapy may be achieved by a cryoprobe or application of liquid nitrogen by spray or by loosely wound cotton on a wooden applicator (not with tightly wound, typical cotton swabs). The full thickness of the wart should be frozen until there is whitening of the surrounding skin area for 2mm. Treatment is repeated weekly until the warts have resolved. Most sexual health clinics have facilities for more focused freezing using fine probes with nitrous oxide or carbon dioxide cryoguns. Patients can be referred for treatment.

**Side effects:** Pain and necrosis following application of cryotherapy are fairly universal, and blistering may occur. The treatment of large warts or areas at one time can create wound care problems. Adverse effects include balanoposthitis, irritation, local oedema, necrosis, ulceration and pain, especially when the treated area thaws. Both hypo- and hyperpigmentation can occur, but this is usually temporary. Although the use of injected local or topical anaesthesia (e.g. Emla cream) is rarely necessary, it may facilitate cryotherapy by reducing pain when a large number or area of warts are present.

## Curettage and scissor or scalpel excision

**Mechanism of action:** Directly remove genital warts.

**Suitable for:** Exophytic warts.

**Contraindications:** Known bleeding abnormality. Can be used in pregnancy.

**Technique:** Direct removal with extension of the wound only into the upper dermis. Haemostasis can be secured with an electrosurgical unit or a chemical styptic (e.g. silver nitrate sticks); suturing is rarely required or indicated when removal is done properly.

**Side effects:** Localised pain, for which mild analgesics may be required, and bleeding. If operating-room surgery is required there are the additional hazards of a general anaesthetic.

## Electrocautery or diathermy (hyfrecation)

**Mechanism of action:** Coagulates proteins of treated tissues.

**Suitable for:** Anogenital and oral warts.

**Contraindications:** None. Can be used in pregnancy.

**Technique:** Requires advance training and expertise to minimise scarring. Once anaesthesia is attained, physical destruction of warts. Usually, no additional haemostasis is required.

**Side effects:** Local pain and possible infection. Scarring is more common than after cryotherapy.

## Laser therapy

**Mechanism of action:** Vaporisation of warts.

**Suitable for:** Vulval, vaginal, cervical and perianal warts. Not considered first line because of expense. Can be considered if there are obstructive lesions.<sup>28</sup> For large lesions, can be combined with electrocautery.

**Contraindications:** None. Can be used in pregnancy.

**Technique:** Adequate training required. Dermal tissue destruction should be limited to 1mm.<sup>28</sup>

**Side effects:** Local pain. Scarring and hypo- or hyperpigmentation can be minimised by controlling depth and avoiding treatment beyond the dermal papillae.

## Podophyllin resin

Podophyllin is no longer recommended as a treatment for genital warts. It has a higher incidence of adverse reactions and reduced efficacy when compared to podophyllotoxin.

## Trichloroacetic acid (TCA)

**Mode of action:** TCA is a caustic agent that destroys warts by chemical coagulation of proteins. Treatment solution concentrations have not been standardised and saturated concentrations of 85-95% have been used.

**Suitable for:** Small warts on moist surfaces.

**Application:** Training is necessary before applying this treatment. TCA solutions should be applied sparingly and allowed to dry before the patient sits or stands. If there is intense pain, the acid can be neutralised with soap and sodium bicarbonate. TCA solution has a low viscosity (comparable to that of water), and if overapplied can spread rapidly and 'run', damaging a significant area of normal tissue.

**Contraindications:** Nil, but most suitable for small moist warts. Can be used in pregnancy.

## 5% flurouracil cream

Not recommended for routine warts because of unproven efficacy, significant toxicity, and teratogenicity. Currently a specialist-only medication. Adverse effects of dysuria, epithelial and urinary meatal erosion, erythema, eschar, hyperpigmentation, local irritation, burning, and itching have been reported.

## Systemic interferon

Not recommended because of expense and side effects and poor efficacy. However, the efficacy of pegylated interferon was demonstrated in one small controlled study in HIV positive patients.<sup>93</sup>

## Selecting treatment(s) for individual patients (see table 3, page 22)

Many patients require a course of therapy rather than a single treatment. Studies have not systematically evaluated the factors that influence the selection of therapy, although a survey found that patients expressed a desire for topically applied therapies that can be used at home. **As no one treatment is ideal for all patients or all warts, consideration should be given to a change of treatment modality or onward referral if there is no significant response within 4 to 6 weeks. Usually patients require a course of therapy, rather than a single treatment.**

Most treatment modalities are eventually effective in eliminating small numbers of warts. Patients with limited disease (i.e. 1 to 5 warts) may benefit most from cryotherapy or simple office surgery. Ablative therapy should be considered in those with large or extensive areas of warts to at least debulk their warts.

For self-applied therapeutic modalities, treatment beyond the manufacturer's recommendations is not advisable and concurrent use of multiple therapeutic modalities on a single wart is not recommended as routine treatment.

**It should be borne in mind that a continuing lack of response to therapy might indicate other pathology and referral for assessment should be considered in such cases.**

Continually evaluate the response to treatment to avoid over-treatment and a therapeutic course worse than the disease itself. Persistent hypo- and hyperpigmentation is a possible complication of ablative therapeutic modalities. Depressed or hypertrophic scars rarely occur. Ablative treatment, especially to the introitus, can result in disabling chronic pain syndrome or hyperaesthesia at the treatment site.

Surgical removal of warts, by diathermy, laser ablation or excision under local or general anaesthesia, may render the patient wart-free, usually in a single visit. However, the disadvantages are that significant training, a moderate amount of equipment, and a longer patient visit are required. Although surgery is obviously of most benefit when warts are present in large numbers or over large surface areas, it can be used for average cases. While the cost of a single surgical visit may be greater, surgery can accomplish in one visit what other ablative modalities often require multiple visits to accomplish, which may result in greater cost-effectiveness for some patients. However, recurrence rates may be the same as other therapeutic modalities and the morbidity of treatment may be greater with increased risk of pain, infection and scarring.

## Combination treatment

Although treatments are commonly combined, few studies have been published which support this practice.

It has been shown that TCA and podophyllin in combination reduce the number of treatments to achieve clearance, compared to TCA alone.<sup>90</sup> A combination of laser and imiquimod has been shown to be safe and well tolerated.<sup>94</sup>

## Symptomatic therapy

- For ongoing management by the GP or health professional, the patient should be advised to return weekly for treatment until all the warts have gone. Patients may be referred to a specialist or sexual health clinic when there is a poor response to treatment, or warts continue to recur after 3 months.
- Saltwater baths are the single most useful thing the patient can do to help soothe and heal the genital area during treatment. 2 handfuls of plain salt per bath or 2 tablespoons in a large bowl, preferably twice daily, and dry with hairdryer.
- Lignocaine gel 2% (Xylocaine™) is a useful local anaesthetic to put on raw areas 2 minutes prior to micturition and defaecation.
- A concomitant thrush infection is common. Local imidazole preparations often help, and/or oral fluconazol.
- For large areas made raw by wart ablations, 1% silver sulphadiazine cream is useful.

## Post treatment follow-up

The benefit, frequency, interval and type of follow-up care necessary after treatment of warts has not been studied. Follow-up evaluation can provide the opportunity for education and counselling of patients. The need to monitor for complications of therapy will vary greatly on the basis of the patient's experience and cognitive ability, the number and location of warts, and the treatment modality used. Patients concerned about recurrences could be offered an evaluation 3 months after successful treatment, since most recurrences occur during this period. In immunosuppressed patients, recurrences of warts are much more common and periodic follow-up evaluation may be necessary.

Patients with genital warts are at risk of other sexually transmitted infections (STIs). Management of genital warts must include careful assessment and testing for other STIs as appropriate, depending on the patient's sexual history.

## Treatment recommendations

- The goal of treatment for genital warts is the removal of visible warts. **GRADE C**
- Standard therapies for genital warts can eventually remove most warts, although no one treatment is ideal for all warts or all patients. **GRADE A & C**
- Clinicians should be knowledgeable about, and have available to them, at least one patient-applied treatment and one health care provider administered therapy. **GRADE C**

## Assessment of sex partners

Sex partners of patients who have genital warts may benefit from examination to assess the presence of genital warts and other sexually transmissible infections, although a specific test for subclinical HPV is not currently available in New Zealand. Sex partners may benefit from counselling about the implications of having a partner who has genital warts. The use of condoms may reduce, but does not eliminate, the risk of transmission to uninfected partners. Female partners of patients who have genital warts should be reminded that cytological screening for cervical cancer is recommended for all sexually active women who have ever had sexual intercourse.

Similarly, the specific benefit of evaluating sex partners of women with HPV-related cervical squamous intraepithelial lesions (SILs) for external genital warts is not known. Although as many as half of male sex partners of women with cervical SILs may have evidence of genital HPV infection, relatively few have external genital warts. It is unclear whether treatment of men with evidence of genital HPV infection influences the natural history of their female sex partner's cervical disease.<sup>95</sup> There is little information available currently about the health effects of HPV-related cervical disease on female sex partners of women with HPV infection.<sup>96</sup> Women who are sex partners of patients with external genital warts should undergo cytological screening for cervical cancer at intervals recommended by national cervical screening guidelines. The benefit of evaluating male sex partners of men with external genital warts is not known.

**Table 1 Treatment by site**

(For details of individual therapies, see Table 2)

Site	Treatment	Use in Pregnancy
External genital warts	<b>Patient applied</b> Podophyllotoxin solution or cream OR Imiquimod 5% cream.	No
	<b>Provider administered</b> Cryotherapy OR Trichloroacetic acid OR Surgical removal OR Laser OR Diathermy.	Yes
Cervical warts (high grade CIN excluded) Vaginal warts	Cryotherapy with liquid nitrogen. Cryoprobe not recommended in vagina because of risk of vaginal perforation/fistula formation. However, the experienced operator can use a bent Cryoprobe with protective sleeve (to stop sticking to the vaginal wall) OR Trichloroacetic acid.	Yes
Urethral meatal warts	Cryotherapy with Cryoprobe (technically difficult with liquid nitrogen). N.B. Risk of stenosis if overzealous treatment. Note: Podophyllotoxin and imiquimod have been used but limited data.	Yes
		No
Anal warts	Cryotherapy. Special open sided anosopes and bent probes are available to permit treatment laterally OR Surgical removal.	Yes
Oral	Cryotherapy OR Surgical removal.	Yes

**Table 2 Summary of treatment options**

Note: All treatments have wide response and recurrence rates. Not all treatments are funded in New Zealand.

Forms of Treatment	Usage	Application Frequency/Duration	Advantages and Disadvantages	Use in Pregnancy
<b>Patient applied</b>				
Imiquimod (Aldara) 5% cream Fully subsidised through Special Authority application (see page 15 for criteria)	External genital warts	Patient should apply once daily at bedtime, 3 times a week for up to 16 weeks. The treatment area should be washed with soap and water 6 to 10 hours post application.	Immune enhancer. May be more effective on moist warts e.g. introitus and perianal areas. Relatively low recurrence rate.	Not recommended. If used, should be registered with 3M monitoring system.*
Podophyllotoxin. Condylone (solution) or Wartec (cream)	External genital warts	Patient should apply podophyllotoxin solution with the supplied applicators, protecting surrounding skin with Vaseline. The cream is applied with a finger, to visible external warts, twice a day for 3 days, followed by 4 days of no therapy. This cycle may be repeated, as necessary, up to 4 cycles. The total wart area should not exceed 10cm <sup>2</sup> , and the total volume of podophyllotoxin solution should not exceed 0.5 ml/day. If possible, the initial treatment should be demonstrated by the health care provider.	Results are dependent on patient compliance and correct application of treatment. Not for large (>10cm <sup>2</sup> ) wart areas and may be less effective on dry warts. Overzealous use can cause painful ulceration. The solution should be used on readily visible warts, particularly in men. The cream preparation may be preferable in women in hard to reach areas.	No

\* 3M Monitoring system in Pregnancy:  
Pharmacovigilance Unit, 3M Health Care Ltd, Morley Street, Loughborough, Leicestershire, LE11 1EP, UK.

Table 2 Summary of treatment options

Continued

Forms of Treatment	Usage	Application Frequency/Duration	Advantages and Disadvantages	Use in Pregnancy
<b>Provider administered</b>				
Cryotherapy (Cryoprobe or liquid nitrogen on prepared swabs)	External anogenital, cervical, urethral, anal or oral warts	Weekly. Freeze full thickness of wart, whitening the surrounding skin area up to 2mm. The size of the swab should be tailored to the size of the lesions e.g. use of orange stick and wrap around cotton wool to obtain correct size.	Effective for moist and dry warts, pain can be reduced by use of local anaesthetic, gel/cream. Safety and efficacy highly dependent on skill level, equipment and experience. Risk of over or under application with liquid nitrogen.	Yes
Electrocautery or diathermy (Hyfrecation)	External anogenital or oral warts	Single treatment.	Prompt wart free state, results depend on skill level and training, requires equipment, longer clinic visit, local anaesthesia is mandatory. Skin bridges should be left in between sites to aid healing and minimise scarring.	Yes
Laser therapy	Extensive anogenital warts	Single treatment.	Prompt wart-free state, may require general anaesthetic. Expensive and only available in a few major centres.	Yes
Surgery	Extensive anogenital, oral or anal warts	Removal by tangential scissor excision, tangential shave excision, curettage or electrosurgery. Treatment can be repeated as required.	Prompt wart free state, results depend on skill level and training, requires equipment, longer clinic visit. Anaesthesia mandatory. Particularly useful for pedunculated warts, and small numbers of anatomically accessible warts.	Yes
Trichloroacetic acid (TCA)	External anogenital, vaginal or anal warts	A small amount should be applied only to warts and allowed to dry, at which time a white "frosting" develops. If an extra amount of acid is applied, the treated area should be powdered with sodium bicarbonate, or liquid soap preparations to remove unreacted acid. Surrounding skin can be protected with petroleum jelly. Can be repeated weekly as required.	Inexpensive, effective for moist and dry warts. Needs careful application by a trained health professional. Not for large areas of friable warts. Low viscosity may result in spreading if over applied, which can cause painful iatrogenic ulceration.	Yes

**Note:** 5-fluorouracil and interferon have been used for treatment of genital warts. However, the use of the former is limited by severe local side effects and of the latter by side effects and expense and are therefore seldom used.

**Table 3 Factors that may influence the selection of treatment for warts**

<b>Patient preferences and characteristics</b>
Preference for self-applied or administered treatments.
Ability to identify accurately and physically reach warts.
Cognitive ability.
Cost of treatment.
Duration of treatment and/or number of visits, distance and work.
Tolerance of pain.
<b>Age</b>
Safety and efficacy of treatments for warts have not been studied in paediatric populations.
When treating, attention should be paid to avoiding and controlling pain associated with treatment. Requiring a parent or guardian to apply a treatment that may be painful is questionable.
Variations in the rate of psychosocial development in adolescence should be taken into account (i.e. cognitive ability to understand and carry out any treatment programme, particularly patient-applied therapy).
<b>Pregnancy</b>
Podophyllotoxin is not recommended and the safety of imiquimod in pregnancy is not known. 5-fluorouracil is a teratogen.
<b>Disease presentation</b>
Wart size and count: in general, provider administered topical treatments are not ideal for large areas of warts, although they may have a debulking effect.
Anatomic location and circumcision status (men): Warts on moist (partially keratinised) surfaces and intertriginous areas appear to respond better to topical treatments than do warts on dry (fully keratinised) surfaces and open areas. Aggressive ablative or surgical therapy should be avoided over the clitoris, glans penis, urinary meatus, prepuce, and prepuccial cavity in uncircumcised men.
<b>Health care provider preferences and characteristics</b>
Clinical training and experience.
Financial and physical resources.
Scheduling limitations.
<b>Immunologic status</b>
Immunocompromised patients may have lower response and higher recurrence rates.

# SPECIAL SITUATIONS

## Pregnancy

### KEY POINTS

- Although genital warts are common in pregnant women, it is rare for babies to develop clinical HPV.
- Transient HPV colonisation in the neonate is common, but persistent infection is unusual.
- Recurrent respiratory papillomatosis is a rare but serious complication of HPV infection in the neonate.
- Ablative methods, e.g. cryotherapy or diathermy, should be used for treatment of genital warts in pregnancy.
- Caesarean section has not been shown to significantly reduce maternal fetal transmission and should be reserved only for outlet obstruction caused by genital warts.

Genital warts can proliferate and become friable during pregnancy, due to the altered immunity as well as increased blood supply. Their removal during pregnancy is often requested by the patient and can be attempted with cryotherapy up to delivery.<sup>97</sup> HPV types 6 and 11 can, rarely, cause laryngeal papillomatosis in infants and children. A Danish study reported an incidence of 7 per 1000 where there was a documented history of external genital warts.<sup>98</sup> A review article states that the overall incidence is 3.5 per million person-years and the prevalence is 4 cases per 100,000 children.<sup>99</sup> In babies born to mothers with genital warts, HPV DNA will be isolated from aerodigestive swabs in a third to a half, but the risk of development of RRP is roughly 1 in 400. Presentation can be at any age, but typically it is at 3 to 4 years with progressive hoarseness. An earlier presentation is often associated with a poorer prognosis, because of multi-centric disease.

Although there appears to be an association between maternal genital warts during vaginal delivery and laryngeal papillomatosis, the route of transmission (transplacental, perinatal, or postnatal) is not completely understood. HPV DNA has been detected in amniotic fluid, raising the possibility of ascending infection, and HPV DNA has been detected in the peripheral blood mononuclear cells of mothers and in cord blood samples.<sup>100</sup> Although this may suggest transmission via a haematogenous route, transmission via microscopic tears in the placental membranes, as occurs with other organisms, is a more likely explanation.<sup>101</sup> There has been a wide variation in reported neonatal transmission rates for HPV, although larger studies using more recent HPV DNA technology indicate that transmission rates are low.<sup>36,37</sup> In a study of 574 women, 47.1% were identified as being HPV DNA positive (mainly in the third trimester) at age < or =24 and 24.4% at age >24. However, 1.6% of newborns were HPV DNA positive at a mean of 65 hours after birth.<sup>102</sup> Non-concordance between parental and neonatal HPV types suggests the possibility of maternal infection acquired antenatally at untested intervals during pregnancy, or in the case of oral infection from other contacts after birth.<sup>83</sup> Follow-up studies of infants from whom HPV DNA was isolated at birth indicate that the virus becomes undetectable in many infants, indicating that contamination rather than true infection has occurred.<sup>103</sup> It has also been demonstrated that HPV 16 antibodies detected at birth will clear from the infant within 10 months, but not from the mother.<sup>103</sup>

**In summary, although HPV infection is frequently detected in pregnant women, detection of HPV in newborns is uncommon and is likely to be due to contamination.**

Although caesarean section reduces the risk of HPV isolation from the neonate, it has not been shown to significantly reduce neonatal transmission of HPV, nor of laryngeal papillomatosis.<sup>98</sup> Many studies have been limited by lack of long term follow-up and assessment of only HPV positivity rates after birth.<sup>104</sup> Caesarean delivery should not be performed solely to prevent transmission of HPV infection to the newborn. In rare instances, caesarean section delivery may be indicated for women with very large genital warts if the pelvic outlet is obstructed or if vaginal delivery would result in excessive bleeding.

Treatment during pregnancy requires some special considerations. Podophyllin and podophyllotoxin should not be used in pregnancy. Maternal and fetal deaths have been reported following the use of podophyllin for large vascular warts. Imiquimod is not recommended as there is insufficient data to recommend its use in pregnant women. Individual case reports and a small case series have been published but usage of imiquimod should be reported to the register of imiquimod use in pregnancy\* which has been established.<sup>105</sup> Appropriate treatments of external genital warts during pregnancy include cryotherapy, TCA or surgical removal, and laser ablation.

HPV in pregnancy has no link with miscarriage, premature labour or other types of pregnancy complications.

## Treatment recommendations

- Podophyllin and podophyllotoxin should not be used in pregnancy. **GRADE C**
- Caesarean section does not significantly reduce vertical transmission and is only indicated when genital warts are likely to cause obstruction of the pelvic outlet or excessive bleeding. **GRADE B**

## Breastfeeding

The use of podophyllin and podophyllotoxin are not recommended in women who are breastfeeding because of systemic absorption. The use of imiquimod is not recommended because of insufficient data. Trichloroacetic acid, cryotherapy, electrocautery and laser can be used during lactation.

## Immunosuppressed patients

Persons who are immunosuppressed because of HIV or other reasons may not respond as well as immunocompetent persons to therapy for genital warts, and they may have more frequent recurrences after treatment. Immunosuppressed women should have cervical Pap smears annually, with early referral for colposcopy if abnormalities are detected. Squamous cell carcinomas arising in SILs resembling genital warts occur more frequently among immunosuppressed persons.

\* 3M Monitoring System in Pregnancy:  
Pharmacovigilance Unit, 3M Health Care Ltd, Morley Street, Loughborough, Leicestershire, LE11 1EP, UK.

# KEY ISSUES IN COUNSELLING

Genital HPV infections are common in people who are sexually active. However, conditioning and social values contribute to individuals having a wide range of emotional responses when given a diagnosis of genital HPV.

## Emotional feelings related to the diagnosis of genital HPV

- Guilt
- Embarrassment
- Sense of isolation
- Loss of assertiveness
- Unworthiness
- Sense of injustice
- Surprise
- Shock
- Dirtiness
- Anger
- Confusion
- Fear
- Denial
- Grief
- Loss of sex life

Good therapeutic management acknowledges these emotional responses and addresses the person's feelings and concerns. Counselling plays an important role and can significantly assist patients with the adjustment of being diagnosed with viral sexually transmitted infection.<sup>106,107</sup> These issues should be addressed at the first presentation. Not all patients will want to take up the offer of counselling and support. Nevertheless, it is important to offer it to all patients so that they can make this decision.

The patient who presents with genital HPV for the first time may feel very vulnerable. It should be acknowledged how difficult it must have been for the person to present for treatment.<sup>108-110</sup> Sometimes the diagnosis is unexpected. The health professional/counsellor should never be dismissive of the patient's disease; for some patients, a diagnosis of genital HPV may be the most challenging health disruption they have experienced, given the stigma associated with sexually transmitted infections. It is important to show empathy and allow time to talk. Counselling and education about genital HPV should take place in an appropriate setting. The following points should be considered:

- Comfortable setting
- Patient dressed
- Minimal interruptions
- Confidentiality assured
- Adequate time
- Attentive listening
- Avoidance of pejorative and prejudicial terms
- Empathic attitude
- Written information to take away and read
- Encouragement to return with list of questions

The educational process may include answering questions about the natural history of the infection. The likely impact of the disease on the patient and how well they are coping should be assessed. Psychological issues and concerns can start to be addressed at the first session. Many patients will be worried about the risk of having acquired HIV or STIs, whether they are seen to be promiscuous, and about the doctor's opinion of them. The emotional consequences and perceived social stigma need to be addressed. The diagnosis of genital HPV may provoke a shock reaction and cause feelings such as guilt, anger, confusion and a sense of isolation.<sup>111,112</sup>

Patients with genital HPV are usually very concerned about the diagnosis of the disease, its potential impact on their lives and how their family and friends will view them. Common concerns of patients relate to having an STI, transmitting the infection, fear of telling potential sexual partners who may then reject them, and how it will affect their sex life and their social activities.<sup>106,111,112</sup> Patients can be reassured that they are not alone in having genital HPV. It is important to provide accurate written information.<sup>112</sup>

## KEY INFORMATION FOR PATIENTS

- Genital HPV (Human Papilloma Virus, more commonly known as wart virus) is a common virus that is carried by a large percentage of sexually active people.
- Not everyone who is infected with HPV will develop genital warts. This depends on their local immunity. Because HPV is such a common infection, genital warts are also very common.  
Most HPV infections do not show any symptoms, so most people do not know when they are infected.
- Getting visible genital warts in a long-term monogamous relationship does not mean the other partner has been unfaithful. It's possible that one or even both were exposed to the virus months or years previously and have carried it in a latent form (invisibly) without showing any symptoms.
- Most genital warts will disappear on their own.  
Genital warts can take some time to disappear, may cause discomfort and are unpleasant to have in such a vulnerable part of your body. There is a variety of treatments available to remove the warty lumps, but they do not necessarily get rid of the underlying virus infection.
- After successful treatment, genital warts may recur – this usually happens for about 1 in 3 people.
- Most HPV infections appear to be efficiently cleared or suppressed by the body's immune system. But it is not known if HPV is completely cleared or remains without symptoms, invisible to the eye.
- After the warts have resolved, some experts believe that your ability to transmit HPV decreases after 18 to 24 months.  
Currently there is no test available to detect whether clearance of HPV has occurred.
- Condoms may reduce the risk of transmission and should be used with new sexual partners. Introducing condoms into a long-term relationship is more debatable because your partner is probably already infected.
- Genital warts do not stop you having children.
- Genital warts do not stop you having sex.
- There is a link between certain types of genital HPV infection and cervical cancer. Women should have regular cervical smears, as per cervical screening programme, to detect early changes which can be monitored and/or treated, thereby preventing their progression to cancer.
- The HPV types that cause external visible warts are rarely associated with abnormalities on the cervix that can cause cancer.

# GUIDELINES ON THE MANAGEMENT OF ANOGENITAL HPV IN CHILDHOOD

## Epidemiology

Following a dramatic increase between 1966 and 1984, HPV is now the most common viral infection of the adult and adolescent female genital tract.<sup>13,113</sup> There are still no long-term natural history studies of anogenital HPV infection in childhood. However, over the same period there was a parallel increase in the number of case reports of anogenital warts in children, which probably reflects a true increase in the childhood prevalence.<sup>114-116</sup>

## Clinical behaviour

HPV infection of the anogenital region is commonly asymptomatic. Children often present because a caregiver has noted the lesions, although some present with pain or bleeding on defaecation, or secondary infection. Classical cauliflower-like condyloma acuminata do occur in children, but anogenital warts have multiple appearances.<sup>117,118</sup>

Many adults have disease at several levels of the genito-urinary tract.<sup>119</sup> Multi-centric disease has rarely been described in children, but it has seldom been looked for.<sup>120</sup>

The incubation period of anogenital warts in adults is widely variable.<sup>1</sup> The incubation period in children is unknown, largely due to the uncertainties surrounding vertical transmission. There is a high likelihood of spontaneous regression over time.<sup>121</sup> HPV may be particularly troublesome in children on immuno-suppressive therapy, and the possibility of immune deficiency (including HIV) should be considered in any child who has particularly refractory lesions.<sup>122,123</sup>

## Virology

Virologic diagnosis relies on the detection of HPV DNA (see page 10). The use of PCR has greatly increased sensitivity, but there is always a risk of contamination. Many HPV types have been described, but no specific type is invariably associated with a particular clinical appearance.<sup>124</sup> Infection with multiple types is common<sup>125</sup> and it is technically impossible to be sure that all types from a given patient have been isolated. HPV DNA can be found in apparently normal tissue surrounding clinical lesions<sup>121</sup> and in vaginal washings from patients with no detectable lesions.<sup>119,126</sup> In adolescents and adults, types 1-4 and 7 are found almost exclusively in skin warts.<sup>124</sup> In children, however, there is a significant prevalence of types 1-3 in anogenital warts.<sup>127,128</sup> Laryngeal papillomas are usually associated with HPV type 6 or 11.<sup>98</sup>

In determining the source of infection, the virology adds little to the history and clinical examination.<sup>129</sup> There is little, if any, value in typing for forensic purposes.

## Neoplasia

In sexually active adolescents and adults, as has already been described, there is a striking association between HPV and dysplasia or carcinoma of the cervix, vulva, penis and anus. Malignancy has been reported in children with laryngeal papillomatosis.<sup>130</sup> The risk of late malignancy in children with anogenital infection is not known. There are case reports of vulval dysplasia and carcinoma in young adolescents who had vulval warts from infancy<sup>131,132</sup> and of Bowenoid papulosis (intraepithelial neoplasia) in childhood.<sup>133,134</sup>

## Methods of transmission in childhood

In adults, genital HPV is a sexually transmitted infection. Sexual transmission clearly occurs in children, but other forms of transmission also occur.

**Sexual transmission:** Adolescent genital HPV is associated with high risk sexual behaviour and early age at first intercourse,<sup>89,135</sup> but is less likely to persist than infection in women who acquire it an older age.<sup>13,89</sup>

It was not recognised until 1971 that anogenital warts in children might be sexually transmitted. From 1971 to 1993, 300 cases were published, of which 29% were sexually transmitted. The percentage of sexual abuse in various studies varies from 0-100%, which may reflect differences either in the populations studied or in the methodology.<sup>117</sup> Sexual abuse has been documented in infants whose warts presented as early as the first year of life,<sup>136</sup> and suggested in some cases of oral or laryngeal papilloma. However, accumulating evidence suggests that the presence of warts in the anogenital region or oropharynx and/or the detection of HPV DNA in the anogenital region is not, in isolation, a reliable indicator of childhood sexual abuse.<sup>101,137-141</sup>

**Vertical transmission:** HPV can be transferred from mothers to their offspring, probably from an infected birth canal.<sup>101</sup> It is difficult to quantify the risk to these babies, but it appears low.<sup>102,142</sup> There is no correlation between the presence of HPV DNA in the baby and the presence or absence of known clinical or virologic infection in the mother. The duration of viral shedding and/or persistence of HPV DNA on the skin of infected babies remains unclear. Although some authors have reported persistence of HPV DNA to 2 years of age,<sup>114,143</sup> another longitudinal cohort study found almost no evidence of persistent perinatally acquired infection.<sup>142</sup>

Vertically-transmitted HPV may also cause juvenile onset respiratory papillomatosis (laryngeal papillomas) that may present as hoarseness, or rarely as recurrent pneumonia or breathing difficulties due to lower respiratory tract involvement.<sup>98</sup> The upper limits of the incubation period from birth to clinical infection have not been established, but in laryngeal disease may be as long as 5 years.<sup>144</sup>

Given that symptom-free infection is common in pregnancy (see above), one cannot completely exclude the possibility of vertical transmission in any child. However, one should remember that maternal infection does not prove vertical transmission. Several cases have been described in which the mother's sexual partner was abusing the child.<sup>145,146</sup> On the basis of the evidence to date, it is reasonable to conclude that most vertical transmission will manifest itself in young children. It has, therefore, been suggested that child sexual abuse is not the most likely cause of HPV in the majority of cases involving children under the age of 4 years.<sup>133</sup>

**Other means of transmission:** Dermatological literature suggests that children may acquire anogenital warts by infection from cutaneous warts on their own hands (auto-inoculation), or on the hands of adults (hetero-inoculation). Arguments for this hypothesis are the prevalence of HPV 2 in anogenital warts in childhood, and a number of suggestive case reports and case series.<sup>37,116,128</sup> Although difficult to prove, some authors have also raised the possibility of fomite transmission.<sup>141</sup>

In conclusion, it must be recognised that methods of transmission other than sexual contact do occur. The most common of these may be vertical transmission. However, this can never be assumed to be the case, and suggestions of auto-inoculation or innocent hetero-inoculation should always be regarded with caution. Sexual contact must be included in the differential diagnosis whenever a child or young person presents with anogenital warts.

## Assessment

Establish the age at which the lesions first appeared, and what symptoms they cause. Consider all means of transmission: vertical (maternal infection including cervical smears; symptoms of respiratory infection); sexual transmission (adolescent sexual activity; disclosure of sexual abuse; behaviour changes; risk factors for sexual abuse, such as contact with a known sexual offender or a family history of sexual abuse); other (other warts in the child or young person; warts in other relatives or caregivers).

Do not forget to examine the whole body (including the conjunctivae, mouth and throat) for warts. Examine the genitalia and anus with a light source and some kind of magnification, such as an auroscope. In females, part the labia and inspect the vulva carefully. In males, do not forget to examine the corona and frenum of the penis (if the foreskin is readily retractile). Not everything that presents as a wart is HPV. The most common alternative diagnosis is molluscum contagiosum, but almost any kind of papular rash may present in the anogenital region. If there is doubt, the lesion may need to be biopsied, and tissue sent both for histology and for virological analysis.

Unless there is clear evidence of vertical transmission in an infant, auto-inoculation in a child or consenting sexual activity in an adolescent, consider referring the patient for a multidisciplinary assessment for possible sexual abuse. If in doubt, consult with a paediatrician with expertise in this area. If you do refer, leave other investigations for sexual abuse to the doctor to whom you are referring. A full assessment for possible sexual abuse will include an examination by a doctor trained in the medical assessment of sexual abuse, a full screen for other STI following accepted forensic procedures, a social work assessment, and a diagnostic interview by an appropriately trained interviewer. In many cases, the result will be inconclusive.<sup>144</sup>

More extensive medical investigations may be needed if there are oral lesions or respiratory symptoms in a young child, or if lesions appear to extend into the anus, urethra or vagina. These might include laryngoscopy, proctoscopy, cystoscopy, vaginoscopy or (in post-pubertal girls) a speculum examination and cervical smear.

## Treatment

Anogenital warts will usually regress spontaneously. Infection may be multi-focal, and HPV DNA is almost certainly present in adjacent 'normal' tissue. At present, there is no evidence that treatment in childhood will reduce the (unproven) risk of later neoplasia. Treatment 'can be difficult, prolonged and only marginally efficacious'<sup>113</sup> and recurrence is common. For all these reasons, active treatment is not usually recommended. Treatment should be reserved for those with significant symptoms. There are many forms of treatment,<sup>141</sup> but in young children with extensive lesions, diathermy under general anaesthetic is probably the best option. Several case reports attest to the safety and efficacy of Podofilox gel (podophyllotoxin) or imiquimod cream in children.<sup>147</sup> However, there are no randomised controlled trials of therapy in childhood. The most common therapy for juvenile onset respiratory papillomatosis is laryngoscopy and surgical debulking with laser. The use of intralesional Cidofovir is under investigation.<sup>148</sup>

## Follow-up

Follow the patient to ensure that the lesions regress, and see them again after 3 to 6 months to ensure that they have not recurred. In the case of vertical transmission, it is important to ensure that the mother receives appropriate follow-up of her own infection. If the patient is a sexually active adolescent, you should screen for other STIs and provide sexual health advice. In the case of sexual abuse, the patient should be followed to ensure that appropriate steps have been taken to ensure his or her ongoing safety and to provide support and counselling.

There is no evidence available to guide recommendations for long-term follow-up. It is reasonable to be concerned that children and adolescents with anogenital HPV infection may be at increased long-term risk of malignancy. Therefore, it would be reasonable to recommend early consultation by patients of either sex for anogenital or urethral symptoms. Routine cervical screening should follow the National Cervical Screening Guidelines.

## References

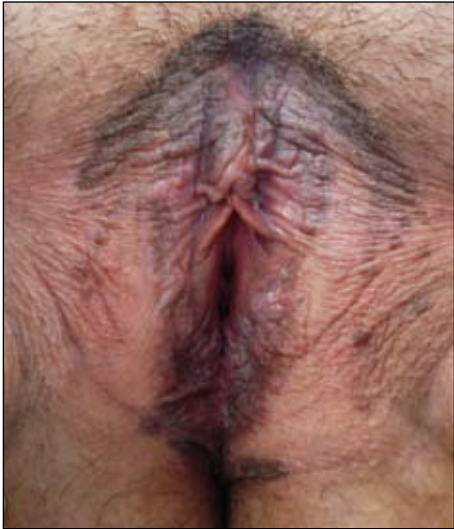1. Burchell AN, et al. Chapter 6: Epidemiology and transmission dynamics of genital HPV infection. *Vaccine*. 2006;24(Suppl 3):S52-61.
2. Clifford GM, et al. Worldwide distribution of human papillomavirus types in cytologically normal women in the International Agency for Research on Cancer HPV prevalence surveys: a pooled analysis. *Lancet*. 2005 Sep 17-23;366(9490):991-8.
3. Garland SM, et al. Human papillomavirus and cervical cancer in Australasia and Oceania: risk-factors, epidemiology and prevention. *Vaccine*. 2008 Aug 19; 26 Suppl 12:M80-8.
4. Trottier H, et al. The epidemiology of genital human papillomavirus infection. *Vaccine*. 2006 Mar 30;24 Suppl 1:S1-15.
5. Partridge JM, Koutsky LA. Genital human papillomavirus infection in men. *The Lancet Infectious Diseases*. 2006 Jan;6(1):21-31.
6. Collins SI, et al. Proximity of first intercourse to menarche and the risk of human papillomavirus infection: a longitudinal study. *Int J Cancer*. 2005 Apr 10;114(3): 498-500.
7. Winer RL, et al. Genital human papillomavirus infection: incidence and risk factors in a cohort of female university students. [see comment] [erratum appears in *Am J Epidemiol*. 2003 May 1;157(9):858]. *Am J Epidemiol*. 2003 Feb 1;157(3):218-26.
8. Brown DR, et al. Detection of multiple human papillomavirus types in Condylomata acuminata lesions from otherwise healthy and immunosuppressed patients. *J Clin Microbiol*. 1999 Oct;37(10):3316-22.
9. Vandepapeliere P, et al. Randomized controlled trial of an adjuvanted human papillomavirus (HPV) type 6 L2E7 vaccine: infection of external anogenital warts with multiple HPV types and failure of therapeutic vaccination. *J Infect Dis*. 2005 Dec 15;192(12):2099-107.
10. Wiley DJ, et al. External genital warts: diagnosis, treatment, and prevention. *Clin Infect Dis*. 2002 Oct 15; 35(Suppl 2):S210-24.
11. Gissmann L, et al. Human papillomavirus types 6 and 11 DNA sequences in genital and laryngeal papillomas and in some cervical cancers. *Proceedings of the Natl Acad Sci USA*. 1983 Jan;80(2):560-3.
12. Habel LA, et al. Risk factors for incident and recurrent condylomata acuminata among women. A population-based study. *Sex Transm Dis*. 1998 Jul;25(6):285-92.
13. Koutsky L. Epidemiology of genital human papillomavirus infection. *Am J Med*. 1997 May 5;102(5A):3-8.
14. Schofield MJ, et al. Sexually transmitted infections and use of sexual health services among young Australian women: women's health Australia study. *Int J STD & AIDS*. 2000 May;11(5):313-23.
15. Dickson N, et al. The lifetime occurrence of sexually transmitted diseases among a cohort aged 21. *NZ Med J*. 1996 Aug 23;109(1028):308-12.
16. Dickson N. Private Communication. 2006.
17. Baseman JG, Koutsky LA. The epidemiology of human papillomavirus infections. *J Clin Virol*. 2005 Mar; 32 Suppl 1:S16-24.
18. Rodriguez AC SM, et al. Longitudinal, prospective study of type-specific carcinogenic HPV infections over 7 years in Guanacaste, Costa Rica. *Proceedings of the 24th International Papillomavirus Conference and Clinical Workshop, Beijing, China 2007*. Abstracts book. Abstract 7B-02.
19. Van Den Eeden SK, et al. Risk factors for incident and recurrent condylomata acuminata among men. A population-based study. *Sex Transm Dis*. 1998 Jul; 25(6):278-84.
20. Manhart LE, et al. Human papillomavirus infection among sexually active young women in the United States: Implications for developing a vaccination strategy. [see comment]. *Sex Transm Dis*. 2006 Aug;33(8):502-8.
21. Wellings K, et al. Sexual behaviour in context: a global perspective. [see comment] [erratum appears in *Lancet*. 2007 Jan 27;369(9558):274]. *Lancet*. 2006 Nov 11; 368(9548):1706-28.
22. Smith A3A, et al. Secondary students and sexual health: results of the 3rd national survey of Australian secondary school students, HIV/AIDS and sexual health. Monograph series No. 47. Melbourne: Australian Research Centre in Sex, Health and Society, Latrobe University, 2003.
23. Adolescent Health Research Group. Youth '07: The Health and Wellbeing of Secondary School Students in New Zealand: Technical Report. Auckland: The University of Auckland 2008.
24. Bearman PS, et al. Chains of Affection: The Structure of Adolescent Romantic and Sexual Networks. *Am J Sociol* 2004:44-91.
25. Brisson J, et al. Condyloma and intraepithelial neoplasia of the uterine cervix: a case-control study. [see comment]. *Am J Epidemiol*. 1988 Aug;128(2):337-42.
26. Nielson CM, et al. Multiple-Type Human Papillomavirus Infection in Male Anogenital Sites: Prevalence and Associated Factors. 2009:1077-83.
27. Nielson CM, et al. Risk factors for anogenital human papillomavirus infection in men. *J Infect Dis*. 2007 Oct 15;196(8):1137-45.
28. Wheeler CM, et al. Determinants of genital human papillomavirus infection among cytologically normal women attending the University of New Mexico student health center. *Sex Transm Dis*. 1993 Sep-Oct;20(5): 286-89.
29. Hildesheim A, et al. Determinants of genital human papillomavirus infection in low-income women in Washington, D.C. *Sex Transm Dis*. 1993 Sep-Oct; 20(5):279-85.
30. Kjaer SK, et al. The burden of genital warts: a study of nearly 70,000 women from the general female population in the 4 Nordic countries. [see comment]. *J Infect Dis*. 2007 Nov 15;196(10):1447-54.
31. Munk C, et al. History of genital warts in 10,838 women 20 to 29 years of age from the general population. Risk factors and association with Papanicolaou smear history. *Sex Transm Dis*. 1997 Nov;24(10):567-72.
32. Feldman JG, et al. The association of smoking and risk of condyloma acuminatum in women. *Obstet & Gynecol*. 1997 Mar;89(3):346-50.
33. Seshadri L, et al. Cervical intraepithelial neoplasia and human papilloma virus infection in renal transplant recipients. *Indian J Cancer*. 2001 Jun-Dec;38(2-4):92-95.
34. Oriel JD. Natural history of genital warts. *Br J Ven Dis*. 1971 Feb;47(1):1-13.

35. Barnabas RV, et al. Epidemiology of HPV 16 and cervical cancer in Finland and the potential impact of vaccination: mathematical modelling analyses. [see comment]. *PLoS Medicine/Public Library of Science*. 2006 May; 3(5):e138.
36. Tang CK, et al. Congenital condylomata acuminata. *Am J Obstet & Gynecol*. 1978 Aug 15;131(8):912-13.
37. Obalek S, et al. Condylomata acuminata in children: frequent association with human papillomaviruses responsible for cutaneous warts. *J Am Acad Dermatol*. 1990 Aug;23(2 Pt 1):205-13.
38. Coutlee F, et al. Risk factors for oral human papillomavirus in adults infected and not infected with human immunodeficiency virus. *Sex Transm Dis*. 1997 Jan;24(1):23-31.
39. Kreimer AR, et al. Oral human papillomavirus infection in adults is associated with sexual behavior and HIV serostatus. *J Infect Dis*. 2004 Feb 15;189(4):686-98.
40. Panici PB, et al. Oral condyloma lesions in patients with extensive genital human papillomavirus infection. *Am J Obstet & Gynecol*. 1992 Aug;167(2):451-58.
41. Yeudall WA, et al. Human papillomavirus DNA in biopsies of oral tissues. *J Gen Virol*. 1991 Jan;72(Pt 1):173-76.
42. Bergeron C, et al. Underwear: contamination by human papillomaviruses. [see comment]. *Am J Obstet & Gynecol*. 1990 Jan;162(1):25-29.
43. Ferenczy A, et al. Human papillomavirus DNA in fomites on objects used for the management of patients with genital human papillomavirus infections. *Obstet & Gynecol*. 1989 Dec;74(6):950-54.
44. Beutner KR, et al. Human papillomavirus and human disease. *Am J Med*. 1997 May 5;102(5A):9-15.
45. Manhart LE, Koutsky LA. Do condoms prevent genital HPV infection, external genital warts, or cervical neoplasia? A meta-analysis. *Sex Transm Dis*. 2002 Nov; 29(11):725-35.
46. Winer RL, et al. Condom use and the risk of genital human papillomavirus infection in young women. [see comment]. *N Engl J Med*. 2006 Jun 22;354(25):2645-54.
47. Munoz N, et al. Chapter 1: HPV in the etiology of human cancer. *Vaccine*. 2006;24(Suppl 3):S1-S10.
48. Beral V. Cancer of the cervix: a sexually transmitted infection? *Lancet*. 1974 May 25;1(7865):1037-40.
49. IARC. IARC monographs on the evaluation of carcinogenic risks to humans. Human Papillomaviruses, vol. 64. Lyon: International Agency for Research on Cancer 1995.
50. Walboomers JM, et al. Human papillomavirus is a necessary cause of invasive cervical cancer worldwide. [see comment]. *J Pathol*. 1999 Sep;189(1):12-19.
51. Bosch FX, et al. The causal relation between human papillomavirus and cervical cancer. [see comment]. *J Clin Pathol*. 2002 Apr;55(4):244-65.
52. IARC. Monographs on the evaluation of carcinogenic risks to humans. Human Papillomaviruses, vol. 90. Lyons: International Agency for Research on Cancer In Press.
53. Clifford G, et al. Chapter 3: HPV type-distribution in women with and without cervical neoplastic diseases. *Vaccine*. 2006;24(Suppl 3):S26-34.
54. Moscicki A-B, et al. Chapter 5: Updating the natural history of HPV and anogenital cancer. *Vaccine*. 2006; 24(Suppl 3):S42-51.
55. Khan MJ, et al. The elevated 10-year risk of cervical precancer and cancer in women with human papillomavirus (HPV) type 16 or 18 and the possible utility of type-specific HPV testing in clinical practice. *J the National Cancer Institute*. 2005 Jul 20; 97(14):1072-79.
56. Lorincz AT, et al. Viral load of human papillomavirus and risk of CIN3 or cervical cancer. *Lancet*. 2002 Jul 20; 360(9328):228-29.
57. Schiffman M, et al. The carcinogenicity of human papillomavirus types reflects viral evolution. *Virology*. 2005 Jun 20;337(1):76-84.
58. Winer RL, et al. Development and duration of human papillomavirus lesions, after initial infection. *J Infect Dis*. 2005 Mar 1;191(5):731-8.
59. McCreddie MR, et al. Natural history of cervical neoplasia and risk of invasive cancer in women with cervical intraepithelial neoplasia 3: a retrospective cohort study. [see comment]. *Lancet Oncology*. 2008 May;9(5):425-34.
60. Jones RW, et al. Vulvar intraepithelial neoplasia: aspects of the natural history and outcome in 405 women. *Obstet & Gynecol*. 2005 Dec;106(6):1319-26.
61. Carcinoma of the cervix and tobacco smoking: Collaborative reanalysis of individual data on 13,541 women with carcinoma of the cervix and 23,017 women without carcinoma of the cervix from 23 epidemiological studies. *Int J Cancer*. 2006 Mar 15;118(6):1481-95.
62. McIntyre-Seltman K, et al. Smoking is a risk factor for cervical intraepithelial neoplasia grade 3 among oncogenic human papillomavirus DNA-positive women with equivocal or mildly abnormal cytology. *Cancer Epidemiology, Biomarkers & Prevention*. 2005 May;14(5):1165-70.
63. Cogliano V, et al. Carcinogenicity of combined oestrogen-progestagen contraceptives and menopausal treatment. [see comment]. *Lancet Oncology*. 2005 Aug; 6(8):552-53.
64. International Collaboration of Epidemiological Studies of Cervical C, International Collaboration of Epidemiological Studies of Cervical C. Cervical carcinoma and reproductive factors: collaborative reanalysis of individual data on 16,563 women with cervical carcinoma and 33,542 women without cervical carcinoma from 25 epidemiological studies. *Int J Cancer*. 2006 Sep 1; 119(5):1108-24.
65. Koutsky LA, et al. A controlled trial of a human papillomavirus type 16 vaccine. [see comment]. *N Engl J Med*. 2002 Nov 21;347(21):1645-51.
66. The FIIISG. Quadrivalent Vaccine against Human Papillomavirus to Prevent High-Grade Cervical Lesions. *N Engl J Med*. 2007 May 10, 2007;356(19):1915-27.
67. Joura EA, et al. Efficacy of a quadrivalent prophylactic human papillomavirus (types 6, 11, 16, and 18) L1 virus-like-particle vaccine against high-grade vulval and vaginal lesions: a combined analysis of three randomised clinical trials. *Lancet*. 2007 2007/5/25;369(9574):1693-702.
68. Garland SM, et al. Quadrivalent vaccine against human papillomavirus to prevent anogenital diseases. [see comment]. *N Engl J Med*. 2007 May 10; 356(19):1928-43.
69. The FUTURE II Study Group. Prophylactic Efficacy of a Quadrivalent Human Papillomavirus (HPV) Vaccine in Women with Virological Evidence of HPV Infection. *J Infect Dis*. 2007;196(10):1438-46.
70. De Carvalho NC, et al. Immunogenicity and safety of HPV16/18 AS04 adjuvanted vaccine up to 7.3 years. abstract 25th International Papillomavirus Conference 8-14 May in Malmo, Sweden. 2009.

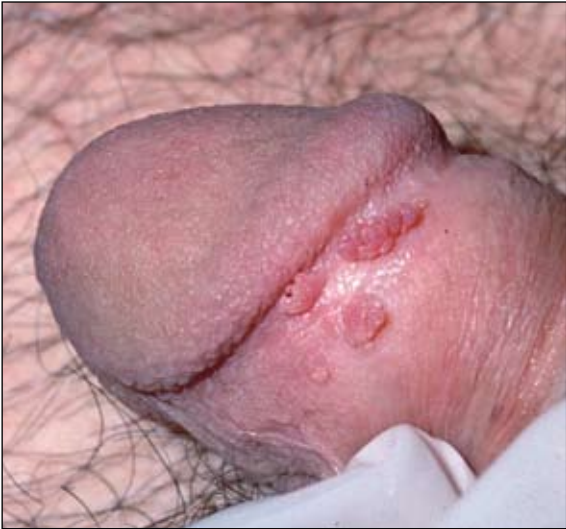71. Harper DM, et al. Sustained efficacy up to 4.5 years of a bivalent L1 virus-like particle vaccine against human papillomavirus types 16 and 18: follow-up from a randomised control trial. *Lancet*. 2006 Apr 15;367(9518):1247-55.
72. Harper DM, et al. Efficacy of a bivalent L1 virus-like particle vaccine in prevention of infection with human papillomavirus types 16 and 18 in young women: a randomised controlled trial. [see comment]. *Lancet*. 2004 Nov 13-19;364(9447):1757-65.
73. Koutsky LA, Harper DM. Chapter 13: Current findings from prophylactic HPV vaccine trials. *Vaccine*. 2006;24(Suppl 3):S114-21.
74. Palefsky J, Giuliano A. Efficacy of the quadrivalent HPV vaccine against HPV 6/11/16/18-related genital infection in young men. Eurogin Conference 2009.
75. Reisinger KS, et al. Safety and persistent immunogenicity of a quadrivalent human papillomavirus types 6, 11, 16, 18 L1 virus-like particle vaccine in preadolescents and adolescents: a randomized controlled trial. *Pediatr Infect Dis J*. 2007 Mar;26(3):201-9.
76. Rowhani-Rahbar A, et al. Long-term efficacy of a prophylactic human papillomavirus type 16 vaccine abstract. 25th International Papillomavirus Conference 8-14 May in Malmo, Sweden. 2009.
77. Ault KA. Long-term efficacy of human papillomavirus vaccination. *Gynecologic Oncology*. 2007 Nov;107(2 Suppl 1):S27-30.
78. Fraser C, et al. Modeling the long-term antibody response of a human papillomavirus (HPV) virus-like particle (VLP) type 16 prophylactic vaccine. *Vaccine*. 2007 May 22;25(21):4324-33.
79. Olsson S-E, et al. Induction of immune memory following administration of a prophylactic quadrivalent human papillomavirus (HPV) types 6/11/16/18 L1 virus-like particle (VLP) vaccine. *Vaccine*. 2007;25(26):4931-39.
80. Stanley M, et al. Chapter 12: Prophylactic HPV vaccines: Underlying mechanisms. *Vaccine*. 2006;24(Suppl 3): S106-13.
81. Burkhart CG. The endogenous, exogenous, and latent infections with human papillomavirus. *Suppl J Dermatol*. 2004 Jul;43(7):548-49.
82. Bunker CB, Neill SM. Male genital dermatology In: Burns T, Breathnach S, Cox N, Griffith C (eds). *Rook's textbook of Dermatology*. Blackwell Publishing 2004.
83. Sterling J. Anogenital Warts. In: Burns T, Breathnach S, Cox N, Griffiths C (eds). *Rook's textbook of Dermatology*. Blackwell Publishing 2004:45-7.
84. Bunker CB, Neill SM. Female genital dermatology In: Burns T, Breathnach S, Cox N, Griffith C (eds). *Rook's textbook of Dermatology*. Blackwell Publishing 2004:70.
85. Sterling J. Vulva intraepithelial neoplasia, penile intraepithelial neoplasia and Bowenoid papulosis. In: Burns T, Breathnach S, Cox N, Griffiths C (eds). *Rook's textbook of Dermatology*. Blackwell Publishing 2004: 55-56.
86. Bunker CB, Neill SM. Erythroplasia of Queyrat, Bowen's disease of the penis and bowenoid papulosis In: Burns T, Breathnach S, Cox N, Griffith C (eds). *Rook's textbook of Dermatology*. Blackwell Publishing 2004:59.
87. Snijders PJ, et al. The clinical relevance of human papillomavirus testing: relationship between analytical and clinical sensitivity. *J Pathol*. 2003 Sep;201(1):1-6.
88. von Krogh G, et al. European guideline for the management of anogenital warts. *Suppl J STD & AIDS*. 2001 Oct;12 Suppl 3:40-47.
89. Ho GY, et al. Natural history of cervicovaginal papillomavirus infection in young women. *N Engl J Med*. 1998 Feb 12;338(7):423-28.
90. Wilson J. Treatment of genital warts - what's the evidence? *Suppl J STD & AIDS*. 2002 Apr;13(4):216-20; quiz 21-22.
91. Coleman N, et al. Immunological events in regressing genital warts. *Am J Clin Pathol*. 1994 Dec;102(6): 768-74.
92. Berman B, et al. Determination of the area of skin capable of being covered by the application of 250 mg of 5% imiquimod cream. *Dermatologic Surgery*. 2004 May;30(5):784-86.
93. Brockmeyer NH, et al. Treatment of condylomata acuminata with pegylated interferon alfa-2b in HIV-infected patients. *Eur J Med Res*. 2006 Jan 31;11(1):27-32.
94. Gunter J. Genital and perianal warts: new treatment opportunities for human papillomavirus infection. *Am J Obstet & Gynecol*. 2003 Sep;189(3 Suppl):S3-11.
95. Bergman A, Nalick R. Prevalence of human papillomavirus infection in men. Comparison of the partners of infected and uninfected women. *J Reprod Med*. 1992 Aug;37(8):710-12.
96. O'Hanlan KA, Crum CP. Human papillomavirus-associated cervical intraepithelial neoplasia following lesbian sex. *Obstet & Gynecol*. 1996 Oct;88(4 Pt 2):702-3.
97. Beutner KR, et al. External genital warts: report of the American Medical Association Consensus Conference. AMA Expert Panel on External Genital Warts. *Clin Infect Dis*. 1998 Oct;27(4):796-806.
98. Silverberg MJ, et al. Condyloma in pregnancy is strongly predictive of juvenile-onset recurrent respiratory papillomatosis. *Obstet & Gynecol*. 2003 Apr;101(4): 645-52.
99. Tasca RA, Clarke RW. Recurrent respiratory papillomatosis. *Arch Dis Child*. 2006 Aug;91(8):689-91.
100. Mandelbrot L. Vertical transmission of viral infections. *Curr Opin Obstet & Gynecol*. 1998 Apr;10(2):123-28.
101. Jayasinghe Y, O'Hanlan KA, Crum CP. Genital warts in children: what do they mean? *Arch Dis Child*. 2006 Aug;91(8):696-700.
102. Smith EM, et al. Human papillomavirus prevalence and types in newborns and parents: concordance and modes of transmission. [see comment]. *Sex Transm Dis*. 2004 Jan;31(1):57-62.
103. Winer RL, Koutsky LA. Delivering reassurance to parents: perinatal human papillomavirus transmission is rare. [comment]. *Sex Transm Dis*. 2004 Jan;31(1):63-64.
104. Medeiros LR, et al. Vertical transmission of the human papillomavirus: a systematic quantitative review. *Cad Saude Publica*. 2005 Jul-Aug;21(4):1006-15.
105. Einarson A, et al. The use of topical 5% imiquimod during pregnancy: a case series. *Reproductive Toxicology*. 2006 Jan;21(1):1-2.
106. Warren T, Ebel C. Counseling the patient who has genital herpes or genital human papillomavirus infection. *Infect Dis Clin Nth Am*. 2005 Jun;19(2):459-76.
107. Reitano M. Counseling patients with genital warts. *Am J Med*. 1997 May 5;102(5A):38-43.
108. Fortenberry JD. Health care seeking behaviors related to sexually transmitted diseases among adolescents. *Am J Public Health*. 1997 Mar;87(3):417-20.
109. Fortenberry JD, et al. Relationships of stigma and shame to gonorrhea and HIV screening. *Am J Public Health*. 2002 Mar;92(3):378-81.

110. Sankar P, Jones NL. To tell or not to tell: primary care patients' disclosure deliberations. *Arch Int Med.* 2005 Nov 14;165(20):2378-83.
111. McCaffery K, et al. Testing positive for human papillomavirus in routine cervical screening: examination of psychosocial impact. [erratum appears in *BJOG*. 2004 Dec;111(12):1489]. *BJOG: Suppl J Obstet & Gynaecol.* 2004 Dec;111(12):1437-43.
112. McCaffery K, et al. Social and psychological impact of HPV testing in cervical screening: a qualitative study. *Sex Transm Infect.* 2006 Apr;82(2):169-74.
113. Centers for Disease C, Centers for Disease C. Condyloma acuminatum - United States, 1966-1981. *MMWR - Morbidity & Mortality Weekly Report.* 1983 Jun 17;32(23):306-8.
114. Rice PS, et al. High prevalence of human papillomavirus type 16 infection among children. *J Med Virol.* 2000 May;61(1):70-75.
115. Oriol JD. Sexually transmitted diseases in children: human papillomavirus infection. *Genitourinary Medicine.* 1992 Apr;68(2):80-83.
116. Cohen BA, et al. Anogenital warts in children. Clinical and virologic evaluation for sexual abuse. [see comment]. *Arch Dermatol.* 1990 Dec;126(12):1575-80.
117. Boyd AS. Condylomata acuminata in the pediatric population. [see comment]. *Am J Dis Child.* 1990 Jul;144(7):817-24.
118. Moscicki AB. Genital HPV infections in children and adolescents. *Obstet & Gynecol Clin Nth Am.* 1996 Sep;23(3):675-97.
119. Spitzer M, et al. The multicentric nature of disease related to human papillomavirus infection of the female lower genital tract. *Obstet & Gynecol.* 1989 Mar;73(3 Pt 1):303-7.
120. Gutman LT, et al. Evaluation of sexually abused and nonabused young girls for intravaginal human papillomavirus infection. *Am J Dis Child.* 1992 Jun;146(6):694-99.
121. Allen AL, Siegfried EC. The natural history of condyloma in children. *J Am Acad Dermatol.* 1998 Dec;39(6):951-55.
122. Cripe TP. Human papillomaviruses: pediatric perspectives on a family of multifaceted tumorigenic pathogens. [see comment]. *Pediatr Infect Dis J.* 1990 Nov;9(11):836-44.
123. Formar AB, Prendiville JS. Association of human immunodeficiency virus seropositivity and extensive perineal condylomata acuminata in a child. *Arch Dermatol.* 1988 Jul;124(7):1010-11.
124. Padel AF, et al. Human papillomaviruses in anogenital warts in children: typing by in situ hybridisation. [see comment]. *BMJ.* 1990 Jun 9;300(6738):1491-94.
125. Davis AJ, Emans SJ. Human papilloma virus infection in the pediatric and adolescent patient. [see comment]. *J Pediatr.* 1989 Jul;115(1):1-9.
126. Stevens-Simon C, et al. The prevalence of genital human papillomavirus infections in abused and nonabused preadolescent girls. *Pediatrics.* 2000 Oct;106(4):645-49.
127. Raimer SS, Raimer BG. Family violence, child abuse, and anogenital warts. *Arch Dermatol.* 1992 Jun;128(6):842-44.
128. Handley J, et al. Common association of HPV 2 with anogenital warts in prepubertal children. *Pediatr Dermatol.* 1997 Sep-Oct;14(5):339-43.
129. Siegfried EC, Frasier LD. Anogenital warts in children. *Advances in Dermatology.* 1997;12:141-66; discussion 67.
130. Bennett RS, Powell KR. Human papillomaviruses: associations between laryngeal papillomas and genital warts. *Pediatr Infect Dis J.* 1987 Mar;6(3):229-32.
131. Boutselis JG. Intraepithelial carcinoma of the vulva. *Am J Obstet & Gynecol.* 1972 Jul 15;113(6):733-38.
132. Lister UM, Akinla O. Carcinoma of the vulva in childhood. *J Obstet & Gynaecol Br Commonw.* 1972 May;79(5):470-73.
133. Godfrey JC, et al. Successful treatment of bowenoid papulosis in a 9-year-old girl with vertically acquired human immunodeficiency virus. *Pediatrics.* 2003 Jul;112(1 Pt 1):E73-76.
134. Breneman DL, et al. Bowenoid papulosis of the genitalia associated with human papillomavirus DNA type 16 in an infant with atopic dermatitis. *Pediatr Dermatol.* 1985 Jul;2(4):297-301.
135. Kahn JA, et al. Mediators of the association between age of first sexual intercourse and subsequent human papillomavirus infection. *Pediatrics.* 2002 Jan;109(1):E5.
136. McCoy CR, et al. Condyloma acuminata: an unusual presentation of child abuse. *J Pediatr Surg.* 1982 Oct;17(5):505-7.
137. Myhre AK, et al. Anogenital human papillomavirus in non-abused preschool children. *Acta Paediatrica.* 2003 Dec;92(12):1445-52.
138. Powell J, et al. Genital carriage of human papilloma virus (HPV) DNA in prepubertal girls with and without vulval disease. *Pediatr Dermatol.* 2003 May-Jun;20(3):191-94.
139. Mant C, et al. Buccal exposure to human papillomavirus type 16 is a common yet transitory event of childhood. *J Med Virol.* 2003 Dec;71(4):593-98.
140. Sinclair KA, et al. Anogenital and respiratory tract human papillomavirus infections among children: age, gender, and potential transmission through sexual abuse. *Pediatrics.* 2005 Oct;116(4):815-25.
141. Sinal SH, Woods CR. Human papillomavirus infections of the genital and respiratory tracts in young children. *Seminars in Pediatric Infectious Diseases.* 2005 Oct;16(4):306-16.
142. Watts DH, et al. Low risk of perinatal transmission of human papillomavirus: results from a prospective cohort study. [see comment]. *Am J Obstet & Gynecol.* 1998 Feb;178(2):365-73.
143. Rintala MA, et al. Transmission of high-risk human papillomavirus (HPV) between parents and infant: a prospective study of HPV in families in Finland. *J Clin Microbiol.* 2005 Jan;43(1):376-81.
144. Kelly P, Koh J. Sexually transmitted infections in alleged sexual abuse of children and adolescents. *J Paediatr & Child Health.* 2006 Jul-Aug;42(7-8):434-40.
145. Hanson RM, et al. Anogenital warts in childhood. [see comment]. *Child Abuse & Neglect.* 1989;13(2):225-33.
146. Herman-Giddens ME, et al. Association of coexisting vaginal infections and multiple abusers in female children with genital warts. *Sex Transm Dis.* 1988 Jan-Mar;15(1):63-67.
147. Majewski S, et al. Imiquimod is highly effective for extensive, hyperproliferative condyloma in children. *Pediatr Dermatol.* 2003 Sep-Oct;20(5):440-42.
148. Kimberlin DW, Malis DJ. Juvenile onset recurrent respiratory papillomatosis: possibilities for successful antiviral therapy. *Antiviral Research.* 2000 Feb;45(2):83-93.

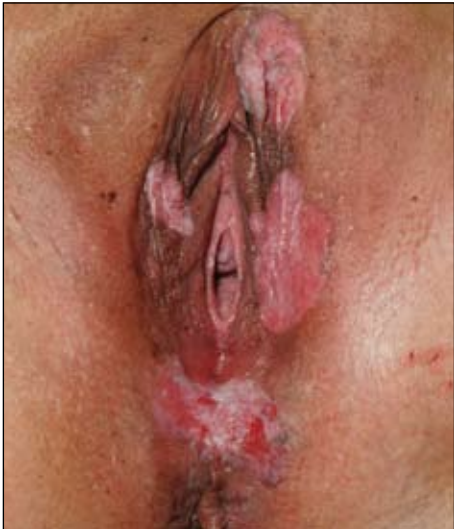# CLINICAL PRESENTATIONS OF GENITAL HPV



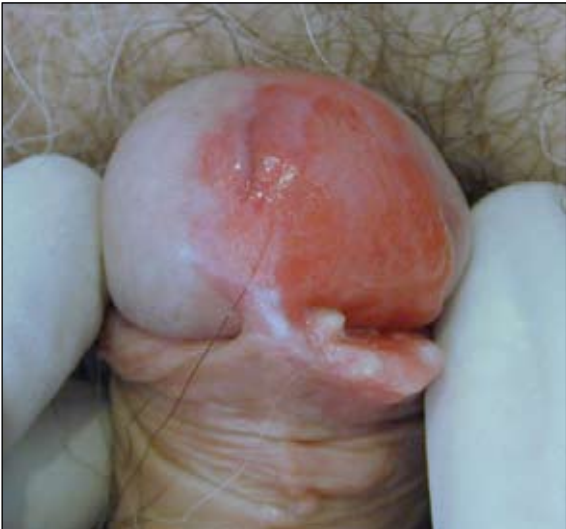Multifocal pigmented VIN



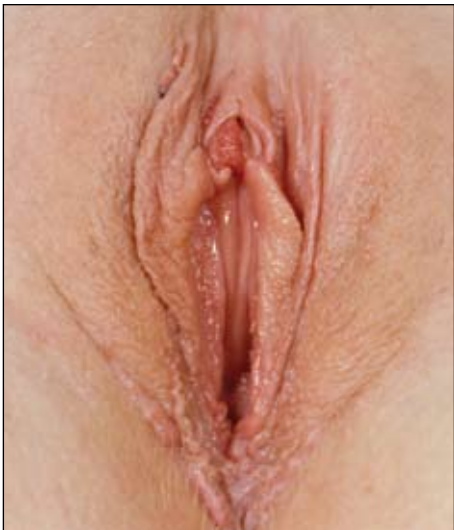Penile warts



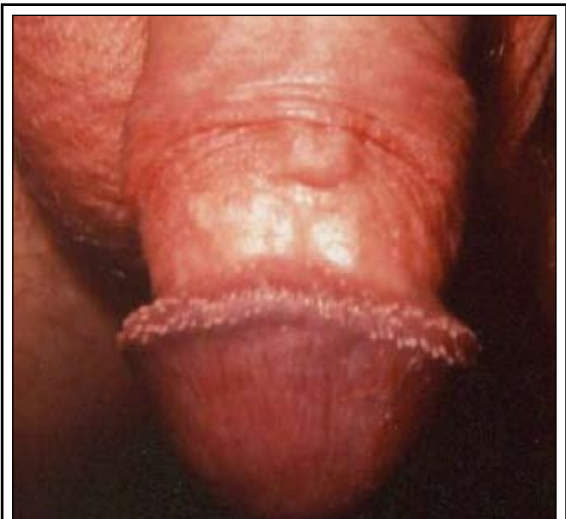Multifocal VIN



Squamous cell carcinoma in situ of glans penis with early invasive carcinoma



Vulval condyloma



- Penile pearly papules, a common benign condition often mistaken for genital warts.

# **Members of the Professional Advisory Board (PAB) of the Viral Sexually Transmitted Infection Education Foundation 2010**

## **Sexual Health Physicians**

Dr Jane Morgan (Chairperson)

Dr Edward Couglan

Dr Janet Say

Dr Nicky Perkins

## **NZ Dermatological Society**

Dr Darian Rowan

## **NZ Committee of the Royal Australian and New Zealand College of Obstetrics and Gynaecology**

Dr Ron Jones (Chairperson, NZHPV Project)

Dr Anne Robertson

Dr Richard Speed

## **Paediatric Society of New Zealand**

Dr Lesley Voss

## **NZ College of General Practitioners**

Dr Phil Jacobs

## **Virology**

Dr Kitty Croxson

## **Family Planning**

Dr Christine Roke

## **Counselling**

Catherine Cook

## **Nursing**

Claire Hurst

Georgina McPherson (NZHPV Project)

Jessie Crawford

## **Patient Advocate**

Jo Patrick

## **Project Co-ordinator**

Claire Hurst, PO Box 2437, Auckland

Tel: 09 433 6526 Fax: 09 360 2835 Email: [info@hpv.org.nz](mailto:info@hpv.org.nz)

# Notes

**The New Zealand HPV Project**  
Viral Sexually Transmitted Infection Education Foundation Ltd

Secretariat:  
PO Box 2437, Auckland 1140, New Zealand  
[info@hpv.org.nz](mailto:info@hpv.org.nz) [www.hpv.org.nz](http://www.hpv.org.nz)

*Supported by an educational grant from  
New Zealand District Health Boards*