

CLINICAL EPISODES OF GENITAL HERPES

Definitions

Primary infection: Recently acquired infection with HSV-1 or HSV-2 with an absence of antibodies to either type on serological testing.

Non-primary infection: Recently acquired infection with a virus type in the presence of antibodies to the other virus type, e.g. HSV-2 in a person with previous antibodies to HSV-1, but absence of antibodies to HSV-2 on serological testing

Recurrence: Previously acquired HSV-1 or HSV-2 infection with antibodies to the same type on serological testing.

First episode: The first clinical episode of genital HSV-1 or HSV-2. This may represent a primary HSV infection or a new non-primary infection or a recurrence of a previously asymptomatic infection. It is not possible to reliably distinguish between these on clinical grounds alone.

First Clinical Episode of Genital Herpes

The first clinical episode of genital herpes may, but does not always, reflect recent infection. Nonetheless, as first episode genital herpes is generally more severe and/or more prolonged. **Treatment should always be offered regardless of time of symptom onset. Do not confuse the treatment of first episode genital herpes with the '72 hour' herpes zoster rule.**

Aciclovir prescriptions do not require specialist authorisation and the medication is available through any pharmacy. Patients are often very unwell and **therapy should be initiated regardless of how long the lesions have been present and before virological confirmation.** This is based on evidence that the virus is shed from the infected area for a median of 11 days, with systemic and local symptoms lasting 2-3 weeks if untreated. Oral antiviral therapy substantially reduces the duration and intensity of symptoms.^{20,21} **GRADE A**

Management for patients presenting with a first episode of genital herpes should encompass the following:

1. History
2. Examination
3. Tests
 - (a) Virus swab for culture or PCR for diagnosis
 - (b) Consider screening for other STIs if appropriate, although this may be deferred to a follow-up visit, as it is often too painful
4. Treatment involving:
 - (a) Oral antiviral therapy
 - (b) Symptomatic treatment
 - (c) Education concerning transmission, epidemiology, etc; provide written material
 - (d) Acknowledgement of the psychosocial impact of the disease
 - (e) Referral to support systems – NZHF Helpline toll free **0508 11 12 13**
5. Appropriate follow-up arrangements

It is not necessary or desirable to attempt to cover all these issues at the initial clinical assessment. However, recognition of the psychosocial impact of the diagnosis, and the provision of adequate information and/or referral to the Herpes Helpline, is important.

It may be helpful to discuss how results will be given, e.g. in person, over the phone. If giving results over the phone, check the person is in an appropriate situation to receive the call.

History of primary genital herpes

Symptoms may appear 2-20 days following infection with the virus. However, initial symptoms of genital herpes may not be recognised or may not occur until months to years later. Symptom severity differs markedly with severe cases having lesions lasting up to 3 weeks.

The prodrome (if experienced) is signalled by flu-like symptoms of fever, headache and general myalgia, accompanied by local tingling, irritation and/or pruritus or pain in the genital region. Rapidly, pruritic erythematous plaques appear followed by a cluster of small vesicles that contain clear to cloudy fluid. These vesicles rupture within 1-2 days to form painful, sloughy, shallow ulcers with irregular margins, which may become confluent. Small ulcerated areas may be surrounded by oedema and be extremely tender. Pain on urination is typical, particularly in women. The ulcers then dry to form crusts and later heal, leaving a transient red macule with minimal scarring (if any). Less commonly, lesions can pass through the blister phase quickly and blisters may not be noticed. Lesions may also appear extra-genitally, commonly on thighs and buttocks and less commonly on hands, lips, face and breasts. Inguinal nodes are usually enlarged and tender.

Complications of primary genital herpes

Neurological complications are more common with genital herpes than is often recognised. Acute, generally benign, lymphocytic meningitis may occur; HSV-2 is associated with aseptic meningitis in up to 36% of adult women and 13% of men with primary HSV-2 infection. Symptoms include neck stiffness, low grade fever and severe headache. Diagnostic features include photophobia with CSF findings of positive HSV-2 PCR, increased white cell count and raised protein.²²

Similarly, a diagnosis of acute radiculitis (herpetic lumbosacral radiculoneuropathy or Elsberg Syndrome) tends to be over-looked yet may cause acute urinary retention, constipation and sacral neuralgia. Referred pain can affect the saddle area distribution, S3 and 4, of the sacral nerve and the bladder detrusor muscle. Erectile dysfunction, dull or severe burning pain in the anogenital region, loss of sensation and hypersensitivity can occur down the thighs and the lower legs. The condition is usually self limiting and tends to resolve in 1-2 weeks; in the meantime, supportive cares should be offered. Symptoms may sometimes persist for weeks and rarely severe intractable pain may require opiate analgesia.

HSV-2 Myelo-radiculitis, associated with advanced immunosuppression and AIDS, may be associated with a fatal outcome.²³

Bells Palsy is probably caused by HSV-1 (and HZV virus). Early treatment with oral steroids is effective;²⁴ the use of antiviral agents is less clear, but is still commonly recommended.

Sporadic herpes simplex encephalitis is an acute necrotizing viral encephalitis that is more usually caused by primary infection with HSV-1. Clinical features are often nonspecific, as is common with all forms of encephalitis, and include headache, signs of meningeal irritation, altered mental status, and seizures. Because prompt treatment of HSV encephalitis may minimise residual neurologic damage and prevent death, early consideration of this diagnosis is important.

HSV is a common predisposing trigger for erythema multiforme. Mild forms of this condition are common and present with mildly itchy, pink-red blotches, starting on the extremities. Some of the skin patches take on the classical 'target lesion' appearance, with a pink-red ring around a pale centre. Resolution within 7-10 days is the norm. Stevens-Johnson syndrome (erythema multiforme major) is a related, much less common, but much more serious condition. Clinically, this may be indistinguishable from toxic epidermal necrolysis and hospitalisation for supportive cares is indicated.

Infrequently, HSV viraemia may result in infection of visceral organs. In most cases of disseminated infection, lesions are confined to the skin, but hepatitis, pneumonitis and other organ involvement may occur, with or without vesicular skin lesions.

Examination

Examination should include inspection of the genital region; speculum examination should be considered, but may need to be delayed if discomfort is anticipated. Clinical diagnosis is insensitive. For example, ulceration may be due to aphthous ulcers, Stevens Johnson syndrome, fixed drug eruption, self-inflicted (sometimes unknowingly) trauma and autoimmune blistering disease (rare). Other infections may cause genital ulcers, e.g. herpes zoster virus, Epstein-Barr virus, primary syphilis and chancroid.

Diagnosis

Laboratory confirmation of the diagnosis is important, but should not delay the initiation of treatment. A negative result does not necessarily exclude a diagnosis of HSV (see page 7).

A. Pharmacological treatment

Therapy should be initiated regardless of how long the lesions have been present and before virological confirmation. **Do not confuse the treatment of first episode genital herpes with the '72 hour' herpes zoster rule.** If there is a possibility of pregnancy, please refer to page 22. Refer immunocompromised patients, or those with herpetic proctitis, to an appropriate specialist, e.g. infectious diseases, sexual health.

1. Oral antiviral treatment

The only funded oral antiviral in New Zealand for first episode herpes is aciclovir; valaciclovir and famciclovir are not subsidised, although this may change as and when generic formulations become available.

Recommended treatment regimens for first episode genital herpes (**all for 5-10 days**) include:

- Oral aciclovir 400mg three times daily (8-hourly) – recommended dose
- Oral aciclovir 200mg five times daily
- Oral famciclovir 250mg twice daily (12-hourly)
- Oral valaciclovir 500mg twice daily (12-hourly)

Lesions may not completely heal over during the course of drug treatment; similarly, mild neurological symptoms may not yet have fully resolved. Nonetheless, a further 5-day course of therapy is not usually indicated unless new lesions continue to appear. Intravenous (IV) aciclovir therapy should be considered for patients who have severe disease or complications that necessitate hospitalisation.²⁵

2. Topical antivirals

Topical aciclovir creams are less effective than oral aciclovir and are not recommended (see page 19).

B. Symptomatic treatment

In addition to oral antivirals, other measures to control symptoms should be suggested. Bathing in salt water (e.g. half a cup of household salt in the bath or 2 teaspoons per litre of warm water for topical application) may help relieve pain and promote healing. Adequate pain relief should be provided. Paracetamol 4-hourly is usually adequate, but stronger pain relief may be necessary. Drinking fluids hourly produces dilute urine that is less painful to void. Female patients can be advised to sit in a bath or bowl of warm water to pass urine. Advice about drying lesions with the lowest setting of a hair dryer may be helpful. Topical anaesthetic jelly such as lignocaine (xylocaine) gel applied 5 minutes before micturition helps relieve the pain. As lignocaine is a potential skin sensitizer, patients should be warned to stop application if increasing discomfort occurs after application. If catheterisation is unavoidable, a suprapubic catheter should be used to reduce the risk of ascending infection and is a less painful option. **GRADE C**

C. Education

It is important to ensure that patients receive accurate up-to-date information about genital herpes. NZHF resources are available to assist patients and clinicians with education and counselling. A range of printed materials can be ordered (please refer to resources listed on inside front cover). Primary care practitioners should have access to these

resources or be able to advise their patients on how to obtain them. www.herpes.org.nz. There is also a Herpes Helpline **0508 11 12 13**, a telephone service that is free to all New Zealanders.

Informing the patient of the diagnosis can be a delicate matter. A diagnosis of genital herpes can have a profound effect on patients.²⁶ They may become upset and distressed; guilt, depression, lowered self-esteem and fear of rejection are common reactions.²⁷ For some, extra-genital (including facial) herpes lesions may also have a considerable psychological impact. Although initial counselling can be provided at the first visit, it may be preferable to wait until the initial outbreak settles to discuss chronic aspects of the infection. Written materials, such as the NZHF **Myth vs Fact** leaflet and **The Facts** book, should be offered to patients at the first visit with discussion and further questions encouraged at the follow-up and subsequent visits.

D. Counselling

Social and psychological issues should be addressed both at the first appointment and at follow-up. There are three main aspects or levels of counselling:

- Basic health counselling (which involves information concerning the disease process).
- Psychological impact of the disease on the patient and their relationships (particularly important in the long term).
- Support offered in the community (e.g. Helpline, support groups).

It may be appropriate to offer the opportunity for their partner to have questions answered as well.

Practice nurses or nurses who have training in this area may also be a good source of counselling support. Useful resources include the NZHF website www.herpes.org.nz, the Herpes Helpline toll free **0508 11 12 13**, or local sexual health clinic, for both management advice and/or more information. Discussing the role of support groups is often helpful; the patient should understand the reassurance that can be gained through discussions with people who have a similar condition; such discussions can be facilitated by the NZHF. The practitioner may also choose to refer patients on to professional counselling, if this is available. Confidentiality and sensitivity are paramount; patients need to agree to a third party becoming involved.

See **Key Information for Health Professionals to Give Patients in Counselling** on page 42. **GRADE C**

E. Follow-up

Follow-up is important for those with first episode herpes. For most patients, one visit is insufficient to properly manage the impact of genital herpes. Counselling and advice often form the major part of a follow-up appointment and time should be allowed for this. The practitioner should be alert to the possibility of further psychological problems manifesting after a diagnosis of genital herpes.

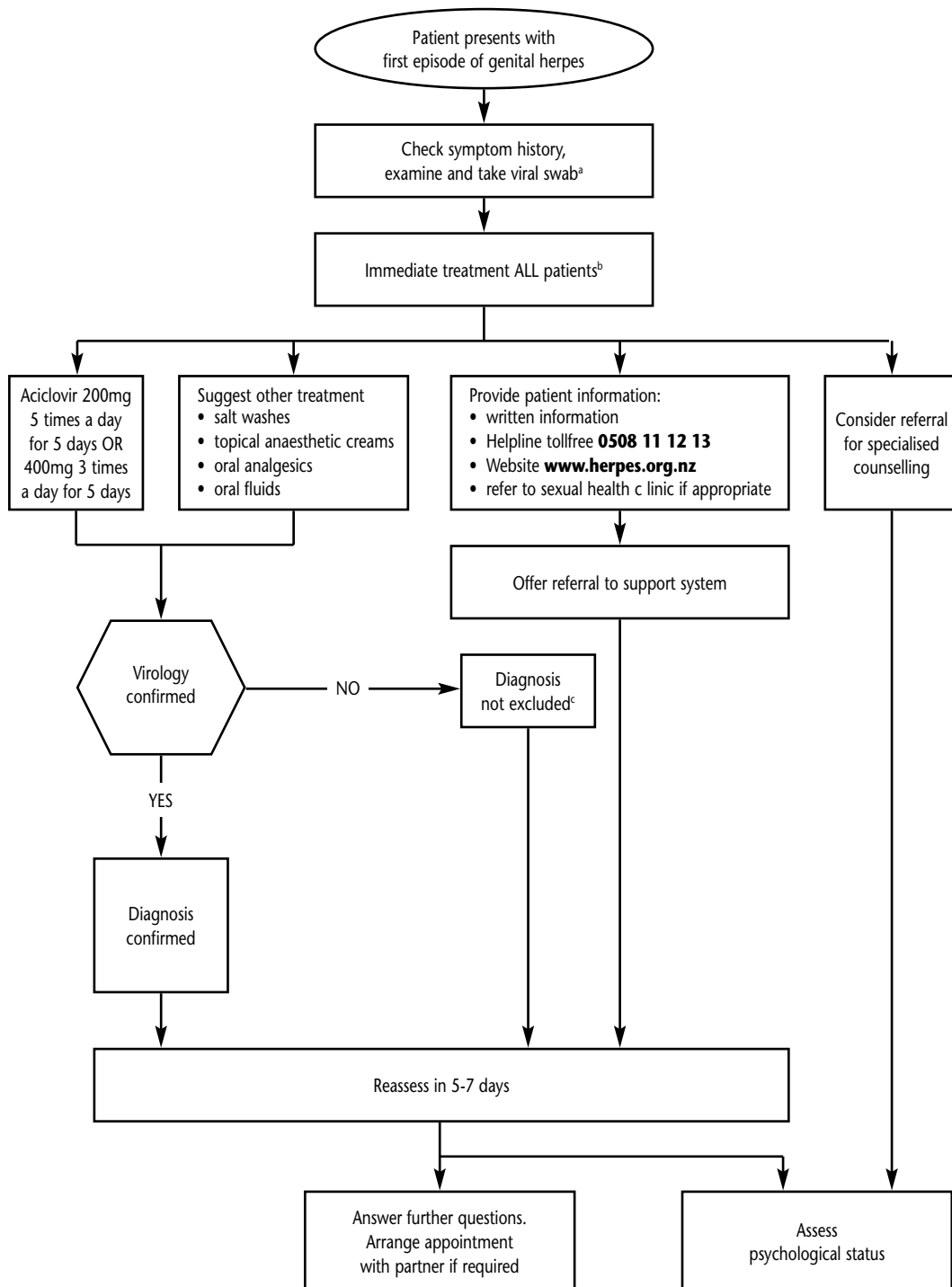
At the initial visit, a follow-up appointment should be offered for 5-7 days later so as to evaluate symptoms, their psychological status, complete a full STI screen if appropriate, discuss results and answer any questions they may have. It should be noted that it might take longer than 5 days for skin lesions to heal completely. Further therapy is not usually required unless new lesions continue to appear. It is also helpful to give anticipatory advice over future management options including oral antiviral therapy; recurrent HSV episodes are usually milder than the initial episode and can be treated with either intermittent therapy (treating each episode) or suppressive therapy (treating continuously over a period of months to prevent episodes).

Suppressive antiviral therapy is recommended for those with frequent and/or severe recurrences or associated psychosocial morbidity. It is suggested that either a minimum of two recurrences or approximately 3 months without suppressive therapy is required to establish the pattern. At all times this process should be one of negotiation with the patient, as the pattern and severity of recurrent episodes is unpredictable.

For those choosing episodic antiviral therapy, this is more effective when patients start therapy themselves at the first signs of a recurrence. This needs anticipatory advice and prescribing. **GRADE A**

Recommendations on counselling and follow-up are based on internationally accepted standards of practice. **GRADE C**

Management of First Episode of Genital Herpes



a In cases of immunocompromised patients or herpes proctitis, refer to specialist.

b Use in pregnancy requires specialist consultation.

c Recommend early presentation for viral swab if recurrence.

Recurrent Episodes of Genital Herpes

Management of recurrent herpes depends on whether there is prior virological confirmation of infection. Management of patients presenting with recurrent herpes should encompass the following:

1. History
2. Examination
3. Tests
 - (a) Virus swab for culture or PCR for diagnosis; confirmation of diagnosis at least once is strongly recommended
 - (b) Consider exclusion of other STIs if appropriate
4. Treatment involving:
 - (a) Consideration of oral antiviral therapy – either intermittent episodic therapy or suppressive therapy where appropriate
 - (b) Symptomatic treatment
 - (c) Education concerning transmission, epidemiology, etc; provide written material
 - (d) Acknowledgement of the psychosocial impact of the disease
 - (e) Referral to support systems – Herpes Helpline toll free **0508 11 12 13**
5. Appropriate follow-up arrangements

Sufficient time should be allowed to address all these aspects. Shared management is important for the patient to feel a measure of control; the clinician should aim to be the facilitator of education and treatment options.

History, examination and diagnosis

Only 10-25% of persons who are HSV-2 seropositive report a diagnosis of genital herpes, which suggests that most have unrecognised symptomatic or completely asymptomatic infections.²⁸ However, once told they are HSV-2 seropositive, more than 50% are able to identify clinically symptomatic recurrences that may have previously been thought to be due to other conditions.

In straight-forward cases with a prior laboratory-confirmed diagnosis, the clinical history is often the principal means of determining that the patient has a recurrent episode, but other genital conditions, e.g. candida (thrush), may mimic and/or coexist with recurrent herpes, and careful examination of the genitalia should always form part of the diagnostic procedure. For example, recurrent ulceration may be due to aphthous ulcers, erythema multiforme, fixed drug eruption, self-inflicted (sometimes unknowingly) trauma and autoimmune blistering disease (rare). Other infections may cause genital ulcers, although not necessarily recurrent, e.g. other herpes viruses such as herpes zoster virus and Epstein-Barr virus, primary syphilis and chancroid.

The atypical or non-ulcerative presentations of genital herpes can mimic most genital diseases, hence the need to consider more than one diagnosis at any given time. For example, lichen sclerosus results in increased skin fragility; because this condition is usually itchy, secondary scratching may cause superficial erosions and haemorrhagic bullae are not uncommon. Eczema and less commonly psoriasis complicated by scratching may cause superficial erosions. Herpes lesions may become secondarily infected with *Staphylococcus aureus* and will give the appearance of a folliculitis, similar to mild forms of hydradenitis suppurativa, primary folliculitis, or scabetic nodules. In most cases extra-genital lesions provide a useful clue to other pathology.

All these examples serve to underpin the importance of taking a detailed history and thorough physical examination of the whole skin, including oral mucosa. Atypical presentation is not unusual and HSV should be considered in any recurrent intermittent inflammatory genital lesions regardless of appearances. **Any recurring lesion of 1-2mm in size, occurring in the same genital area, is strongly suggestive of HSV-2 infection.**

All genital lesions not previously diagnosed should have a viral swab taken with an explanation to the patient why this has been done. **GRADE B**

It is desirable, but not always possible, to obtain virological confirmation. Typically, the viral load is reduced in recurrences compared with the first episode. There is a significant false-negative rate in the laboratory tests for HSV, although this is less for PCR. The best method of obtaining confirmation during a recurrence is to take a swab for culture or PCR within 24 hours of symptoms developing. **GRADE B.**

An option is to instruct patients how to take a swab themselves and deliver direct to the laboratory. Other causes of recurrent genital lesions should be considered, but in the event of continuing recurrent lesions and viral culture swabs remaining negative, PCR testing of lesions or type-specific herpes serology testing may aid diagnosis.

Complications of recurrent genital herpes

Herpes recurrent lesions can occur on the hands, arms, shoulders and other areas of the body, commonly around the buttocks; the diagnosis is often overlooked.

Lumbar sacral radiculopathy can recur, but usually with less severe symptoms than in primary infection. Recurrent, benign, aseptic meningitis, known as Mollaret's meningitis, may occur with HSV-2. Patients should be offered long-term suppressive antiviral management which may need to be continued indefinitely.

HSV is a common predisposing trigger for erythema multiforme. Mild forms of this condition are common and present with mildly itchy, pink-red blotches, starting on the extremities. Some of the skin patches take on the classical 'target lesion' appearance, with a pink-red ring around a pale centre. Resolution within 7-10 days is the norm. Recurrent episodes may be managed with continuous antiviral suppression treatment. Stevens-Johnson syndrome (erythema multiforme major) is a related, much less common, but much more serious condition. Clinically, this may be indistinguishable from toxic epidermal necrolysis and hospitalisation for supportive care is indicated.

Education and counselling

It is important to ensure that patients receive accurate up-to-date information about genital herpes. NZHF resources are available to assist patients and clinicians with education and counselling. A range of printed materials can be ordered – please refer to resources listed on inside front cover – primary care practitioners should have access to these resources or be able to advise their patients on how to obtain them. Written materials, such as the NZHF **Myth vs Fact** leaflet and **The Facts** book, should be offered to patients with discussion and further questions encouraged at subsequent visits. Useful resources include the NZHF website **www.herples.org.nz** and the Herpes Helpline toll free **0508 11 12 13** or the local sexual health clinic for both management advice and/or more information.

It is important to understand the impact that a diagnosis of genital herpes may have.²⁷ Issues that should be raised with patients (and perhaps their partners) include:

- The effect of genital herpes on self esteem and self image
- How herpes will affect their current relationships
- How herpes will affect their ability to form new relationships
- The disclosure of their condition to partners or potential partners
- The lifelong nature of the condition and how this affects them
- Fears concerning transmission or the infectious nature of the disease
- Fears concerning future fertility
- Fears concerning cancer
- Fear of discovery
- Alterations in social activities and lifestyle
- Stress management
- Feelings of isolation
- The attitude of the general public towards this disease

For **Key Information for Health Professionals to Give Patients in Counselling**, see page 42.

People with genital herpes may become anxious or depressed and this may unmask or amplify disorders such as phobias or obsessive-compulsive disorder. Specialist referral may be necessary for severe or complicated cases. In general, assisting the patient to take responsibility for, and control of, their disease and its treatment will help the patient overcome some of the psychological difficulties. **GRADE B**

Recommendations on education and counselling and follow-up are based on internationally accepted standards of practice. **GRADE C**

Episodic antiviral therapy

The aim of episodic treatment is to reduce symptoms and duration of viral shedding during recurrences, rather than reduce the frequency of recurrences. Further, early therapy may abort episodes, that is, lesions may be prevented from progressing beyond the papular stage.^{29,30} In situations where patients have well recognised prodromes and/or have less frequent recurrences, some may find episodic treatment preferable to continuous suppressive therapy.

Effective episodic antiviral treatment of recurrent herpes requires initiation of therapy during the prodrome that precedes some outbreaks or within one day of lesion onset.^{29,30} Beyond this time frame, there is no clear benefit so it is important that a prescription is readily available. In consultation with the patient, sufficient quantities of medication may be prescribed with instructions to start treatment as soon as symptoms begin. Shorter courses of patient-initiated therapy, e.g. single-day famciclovir³⁰ or two days of aciclovir,³¹ have been shown to be as effective as a longer 5-day course. **GRADE A**

Recommended dosage regimen

If the patient is pregnant, specialist consultation is recommended (see page 22).

In cases of immunocompromised patients, refer to appropriate specialist.

Treatment regimens for intermittent episodes include:

For five days:

- Oral aciclovir 400mg three times daily (recommended)
- Oral aciclovir 200mg five times daily
- Oral valaciclovir 500mg twice daily
- Oral famciclovir 125mg twice daily*

Short-course:

- Oral aciclovir 800mg three times daily for two days (recommended)
- Oral valaciclovir 500mg bd for three days
- Oral famciclovir 1gram bd for one day*

***Note:** Famciclovir is not subsidised or marketed in New Zealand.

Suppressive antiviral therapy

Suppressive therapy is an oral antiviral taken continuously over a given period of time that effectively reduces the frequency of recurrences.^{32,33} **GRADE A**

The main aims of suppressive therapy are:

- As an effective strategy for improving the quality of life of patients with recurrent genital herpes.^{34,35}
- To empower the patient, giving them a measure of control over the disease process.
- To allow the patient to have a break from experiencing recurrences of the disease.

In a recent study, suppressive once daily valaciclovir resulted in reduced transmission to an uninfected partner; there was a 48% reduction in acquisition of HSV infection and a 75% reduction in clinical symptomatic genital herpes.¹⁶ Other antivirals may be similarly effective, but this has not been proven in clinical trials. Patients may wish to consider this as a useful adjunct to safer sex behaviour and the use of condoms for the prevention of genital herpes transmission.

Indications for suppressive therapy

Suppressive therapy should be considered in the following circumstances:

- Frequent and/or severe recurrences or associated psychosocial morbidity. Consider suppressive therapy in conjunction with other management. **GRADE B**
- For HSV-2 positive male partners of pregnant women (see page 28).

With long-term suppressive therapy it is strongly advisable to have virological confirmation of the diagnosis before commencing treatment. **Patients who do not have virological confirmation of recurrences or who have complications or severe problems relating to their herpes should see a specialist.**

Recommended dosage regimen

If the patient is pregnant, specialist consultation is required (see page 22). In cases of immunocompromised patients, refer to appropriate specialist.

Recommended treatment regimens for suppressive therapy include:

- Oral aciclovir 400mg twice daily
- Oral aciclovir 200mg four times daily
- Oral valaciclovir 500mg once daily (now available, see Note below)
- Oral famciclovir 250mg twice daily*

Note: Valaciclovir (Valtrex™) is listed for suppressive treatment of recurrent genital herpes, subject to a Special Authority restriction, in the Pharmaceutical Schedule.

- **Initial application:** From any practitioner. Approvals valid for 12 months where the patient has genital herpes with two or more breakthrough episodes in any 6 month period while treated with aciclovir 400mg twice daily.
- **Renewal:** From any practitioner. Approvals valid for 12 months where the treatment remains appropriate and the patient is benefiting from treatment.

*Famciclovir is not currently subsidised or marketed in New Zealand, although this may change as and when generic formulations become available.

The duration of therapy should be negotiated between the patient and the clinician; however, a treatment period of a year is recommended with periodic reassessment. Patients should be given a reasonable break from therapy to reassess their pattern of recurrence to determine whether it has reduced with time. **GRADE C**

20-25% of patients may experience recurrent episodes whilst on suppressive therapy.^{33,36} Other genital conditions may mimic and/or coexist and, even if symptoms are suggestive of breakthrough recurrences, such patients are advised to see a specialist. The usual recommended dose of aciclovir may need to be altered if breakthrough episodes are confirmed; aciclovir has poor oral bioavailability and some patients require multiple doses throughout the day. Alternatively, a trial of Valaciclovir (Valtrex™) may be considered for these patients; Famciclovir is not currently subsidised in New Zealand.

Suppressive therapy does not alter the natural history of recurrences long term and it is common to have a recurrence soon after withdrawal of therapy. It is helpful to anticipate this and to provide sufficient medication to allow prompt self-initiated treatment of any early recurrences. It is suggested that either a minimum of two recurrences or approximately 3 months without suppressive therapy is necessary to establish the new pattern. At all times this process should be one of negotiation with the patient, as the pattern and severity of recurrent episodes is unpredictable.

Some patients may need to be on suppressive therapy for years. Aciclovir is well tolerated and safety and efficacy data are supportive of longer-term use.³⁷ Neurotoxicity (lethargy, confusion, hallucinations and involuntary movements) has been reported in those with renal impairment.

Intermittent suppressive antiviral therapy

The use of intermittent suppressive therapy is also considered a point for negotiation with the patient. Practitioners should be aware that this type of therapy is an option, particularly for patients who are keen to avoid a recurrence during a specified period, e.g. a holiday, exams, etc. **GRADE C**

Topical antiviral therapy

Topical aciclovir creams may be helpful for mild recurrences in some patients,³⁸ but are less effective than oral aciclovir. Further, not all topical formulations are bioequivalent.³⁹ Hence, use of topical treatment is not recommended. Topical antiviral creams are available over the counter, but are no longer subsidised on the pharmaceutical schedule.

Newer topical agents such as immune modulators are currently in clinical trials.

Other therapies

Evidence for other therapies (oral L-lysine, aspirin, liquorice root cream, lemon balm, aloe vera cream, etc.) is limited and should be considered as such.²⁵

Management of Genital Herpes in Immunocompromised Individuals

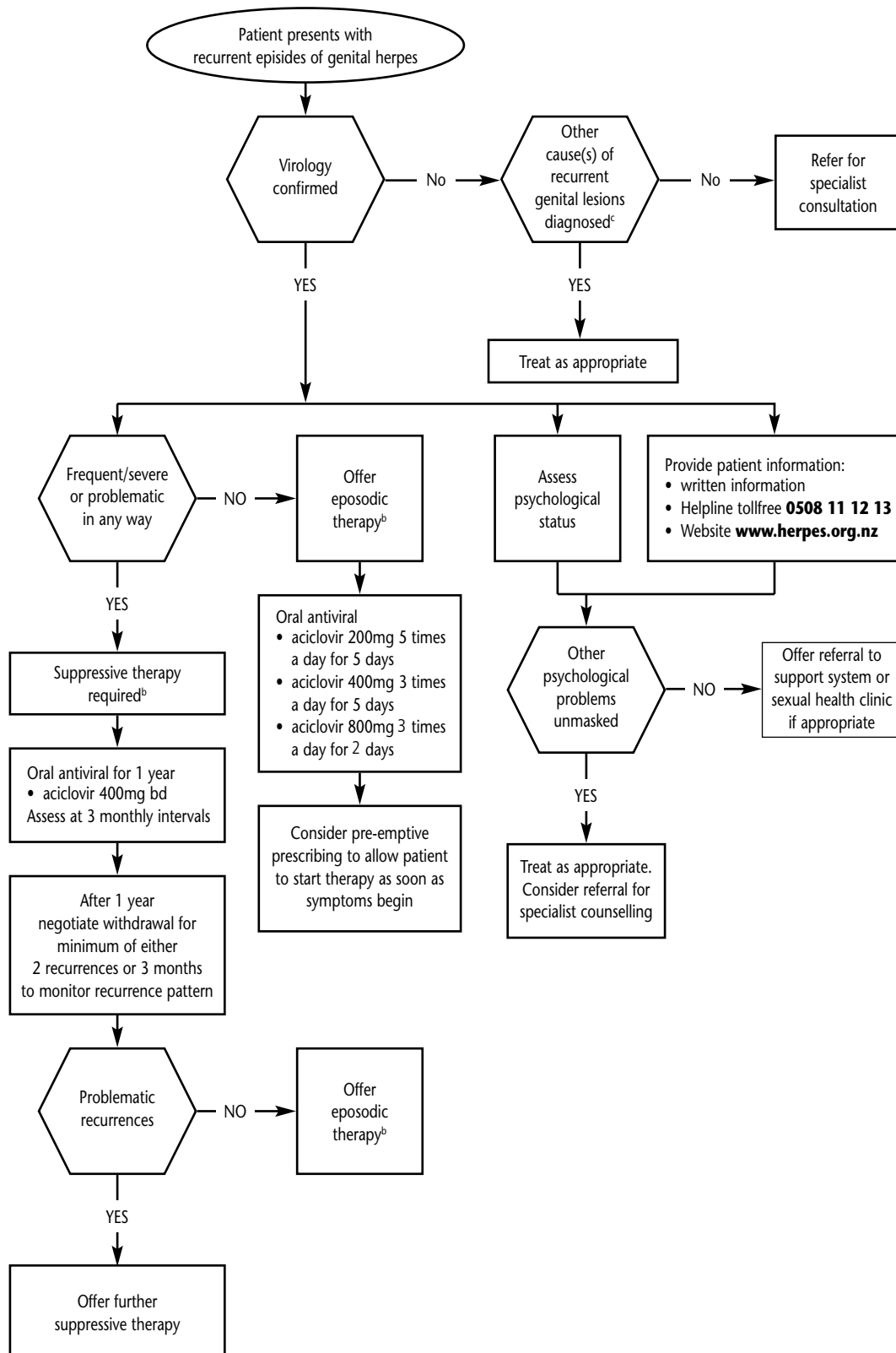
Although rare in immunocompetent individuals, clinically refractory (large, severe and sometimes atypical) lesions due to genital HSV may occur in patients with severe immunodeficiency, including late stage HIV disease. Immunocompromised individuals need referral to specialist care.

Summary Statements Concerning the Treatment of Genital Herpes

- Oral, not topical, antivirals should be prescribed. Do not confuse the treatment of first episode genital herpes with the '72 hour' herpes zoster rule.
- Analgesia and topical anaesthetic jellies can be suggested if necessary. Encourage intake of oral fluids. Patients should be advised to bathe herpetic lesions in salt water, and women be advised to urinate in a warm bath to prevent pain.
- Effective episodic treatment of recurrent herpes requires prompt initiation of therapy during the prodrome or within one day of symptom onset. Sufficient quantities of medication may be prescribed with instructions to start treatment as soon as symptoms begin.
- Suppressive therapy should be considered for those with frequent and/or severe recurrences or associated psychosocial morbidity. Consider suppressive therapy in conjunction with other management.
- Standard therapy in New Zealand for suppression of herpes recurrences is oral aciclovir 400mg twice daily. The recommended period of treatment is 12 months, with review at 3-month intervals. Repeat year-by-year, if necessary.
- Withdrawal of therapy should be for a sufficient length of time to establish whether the pattern of recurrence has changed, for example, a minimum of two recurrences or for 3 months.
- Current generic brands of aciclovir are fully subsidised and, in 2009, cost:

aciclovir	200mg x 25 tabs = \$2.50	ex manufacturer
aciclovir	400mg x 56 tabs = \$7.50	ex manufacturer
aciclovir	800mg x 35 tabs = \$8.30	ex manufacturer

Management of Recurrent Episodes of Genital Herpes



- a In cases of immunocompromised patients or herpes proctitis, refer to specialist.
- b Use in pregnancy requires specialist consultation.
- c Recommend self-applied swab or early presentation for viral swab if recurrence.